

An Evaluation of 4 Patients Post Negative Pressure Wound Therapy Using a Foam Dressing Containing 0.5% Polyhexamethylene Biguanide (PHMB)

Kathleen Leak, Wound Care Sister, Doncaster and Bassetlaw Hospitals NHS Foundation Trust, Armthorpe Road, Doncaster;
Susan Johnson, Lead Nurse: Tissue Viability, Doncaster and Bassetlaw Hospitals NHS Foundation Trust, Armthorpe Road, Doncaster;
Pam Spruce, Clinical Director TVRE Consulting, Broadview, Blurton Road, Barlaston

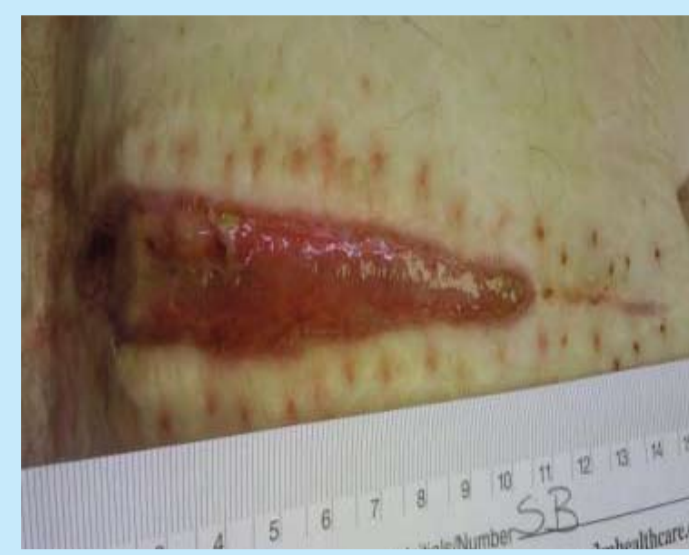

Figure 1

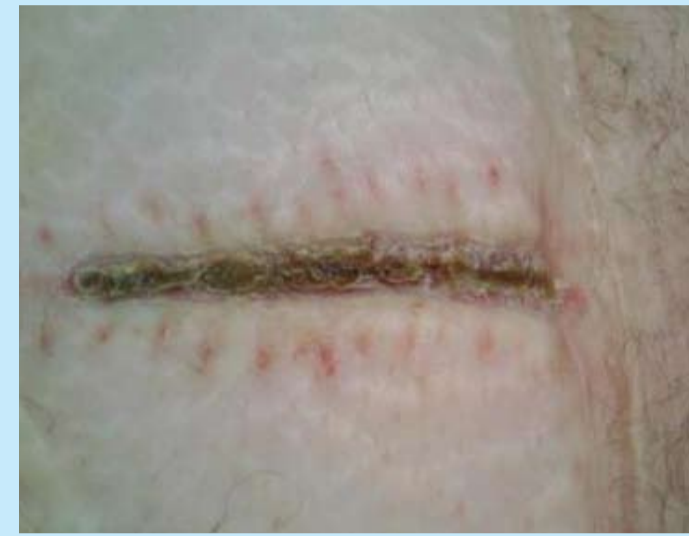

Figure 2

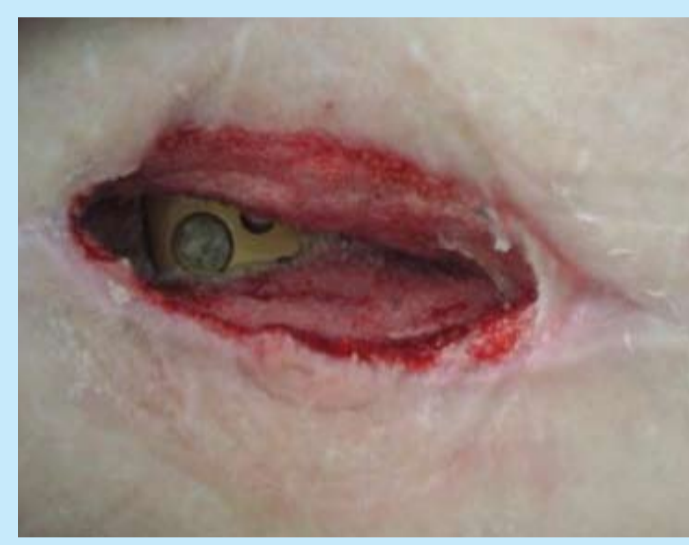

Figure 3: Wound at presentation

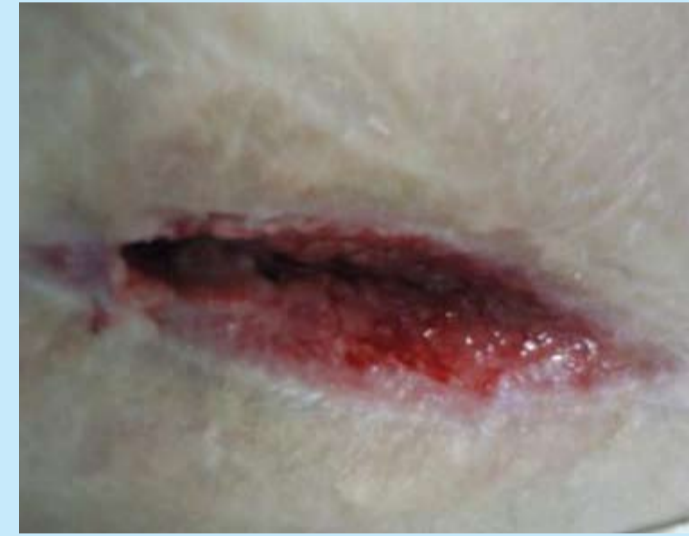

Figure 4: Wound after 4 weeks NPWT

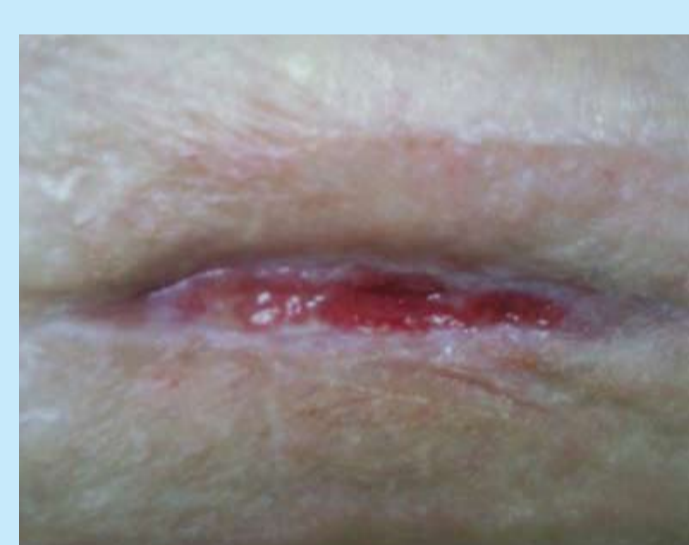

Figure 5: After 3 weeks application of Kendall AMD antimicrobial foam dressing

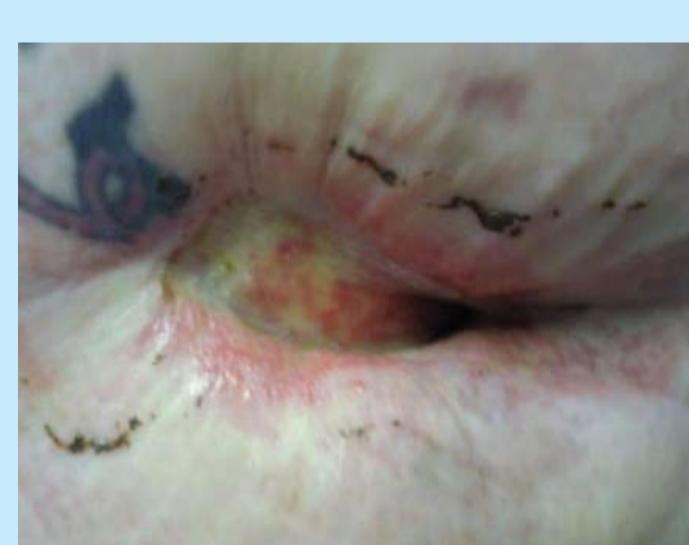

Figure 6: Wound prior to NPWT

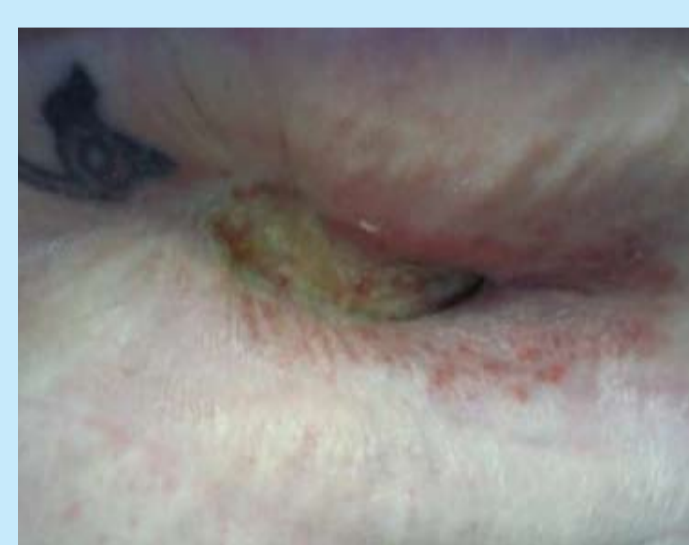

Figure 7: Wound after 3.5 weeks and prior to Kendall AMD antimicrobial foam dressing

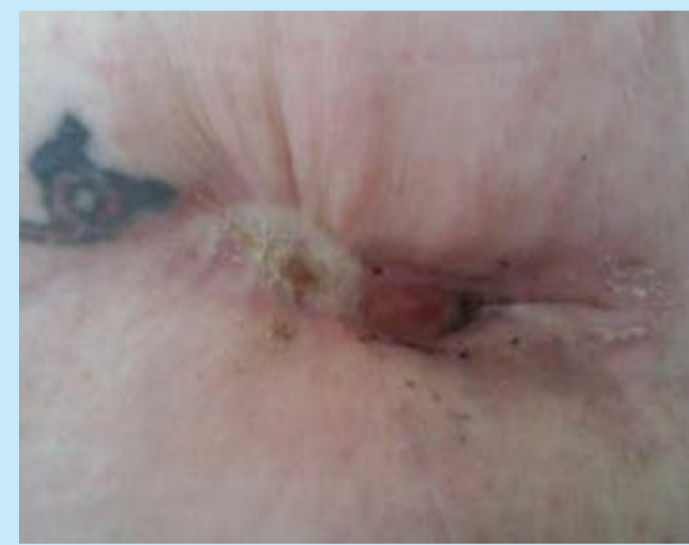

Figure 8: Mastectomy wound after 5 weeks of Kendall AMD antimicrobial foam dressing

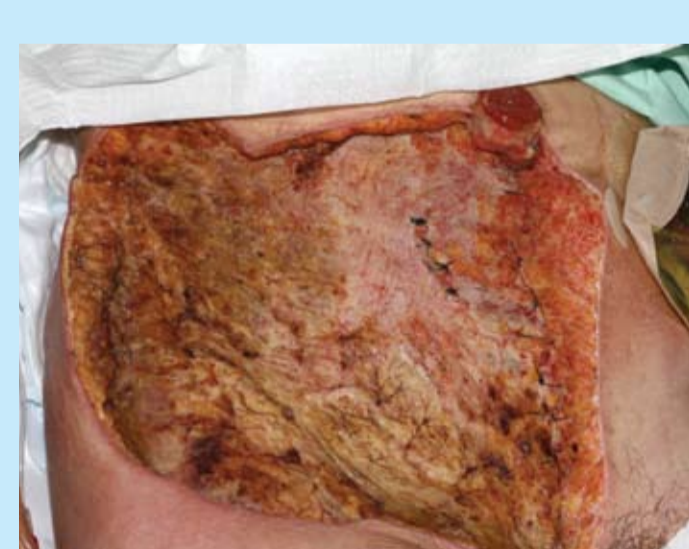

Figure 9: Wound on presentation to the Wound Care Service

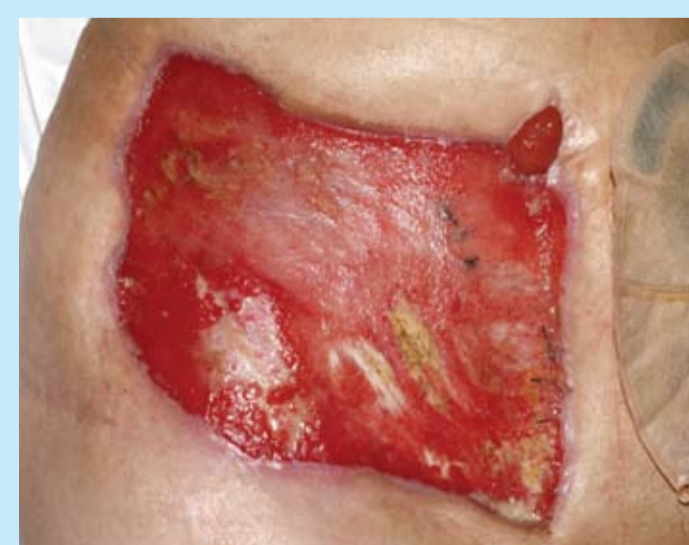

Figure 10: Wound after 7 weeks of NPWT prior to Kendall AMD antimicrobial foam dressing

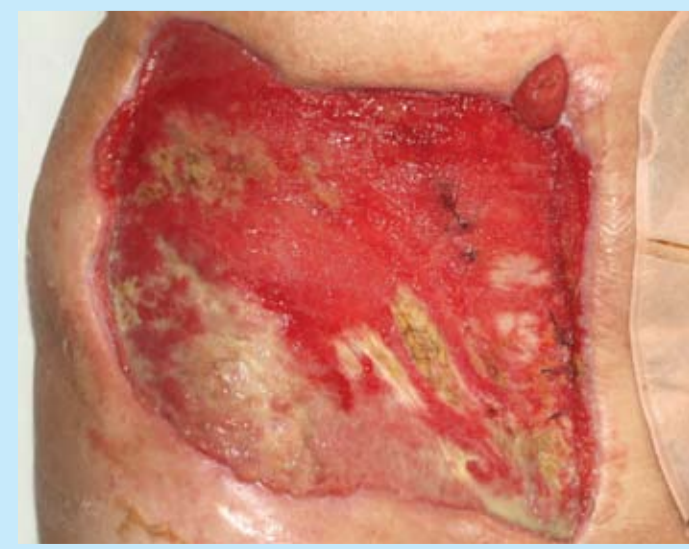


Figure 11: Wound to date – epithelial margins progressing

Introduction

The use of Negative Pressure Wound Therapy (NPWT) is an integral part of the management of complex wounds within the Doncaster and Bassetlaw NHS Foundation Trust Acute Hospitals. As the demand for this therapy increases, the challenge for the Wound Care Service is to ensure that the systems are used effectively. This involves the application and removal of the devices at appropriate times, and effective follow up to ensure that the wound continues to progress.

Method

Antimicrobial foam dressings are generally used for a short period of time following NPWT within the Wound Care Service. With the introduction of a polyhexamethylene biguanide (PHMB) impregnated foam dressing (Kendall™ AMD antimicrobial foam dressing, Tyco Healthcare Group LP d/b/a Covidien, Mansfield, MA, 02048, USA), the decision was made to undertake a small evaluation on 4 patients. This evaluation's objective was to observe the dressing's effectiveness in managing exudate and helping to prevent infection in the immediate post NPWT episode of care.

While clinical effectiveness is of vital importance, it is also necessary to consider the cost implications when introducing any new product into the Wound Care Formulary. This includes any immediate cost savings – for example a cost reduction in the unit price of a dressing.

The NPWT system of choice within the Trust is one which uses PHMB impregnated gauze (Kendall AMD antimicrobial foam dressing) as the cavity filler within the Chariker-Jeter technique. Therefore it was appropriate to continue with the same antimicrobial agent, but in a dressing which would manage exudate effectively.

Data were collected on each patient to evaluate:

- The progress of the wound using NPWT, including the reason for application and the condition of the wound at the time of removal.
- The amount of exudate, clinical signs of infection, and whether there was any wound odour at the time of removal.
- The progress of the wound using the PHMB impregnated foam dressing (Kendall AMD antimicrobial foam dressing), including the management of exudate, and its effectiveness in controlling wound odour.
- Factors which may have an influence on the cost of care, including the frequency of dressing change, the cost of dressings, and whether the change of treatment facilitated early patient discharge.

Results

Case 1.

- Forty-four year old female with a history of diabetes, who had a dehisced oophorectomy wound following surgery for endometriosis.
- NPWT was used for 3 weeks to control exudate and promote wound healing.

- Kendall AMD antimicrobial foam dressing was then used to help prevent infection, because of the increased risk of infection as a result of the diabetes (Figure 1 shows the wound after the NPWT was removed and prior to Kendall AMD antimicrobial foam dressing).
- One 10cm x 10 cm dressing was used to cover the wound, which was changed twice weekly.
- The wound remained clean and granulating, with no odour. It was treated with Kendall AMD antimicrobial foam dressing for 10 days at which point the wound had fully epithelialised. Figure 2 shows the wound at this time point.
- The patient was treated on an out-patient basis throughout the course of care.

Case 2

- Seventy-two year old female who had undergone surgery for a fractured hip and the wound over the prosthetic hip had dehisced. Figure 3 shows the wound prior to NPWT – the prosthetic hip can be observed in the wound bed.
- The patient had been transferred from another hospital with a foam based NPWT device in situ, but the wound had not progressed.
- The gauze-based NPWT device was used for 4 weeks, at which point the wound bed was granulating well. Figure 4 shows the wound immediately prior to Kendall AMD antimicrobial foam dressing being applied.
- Kendall AMD antimicrobial foam dressing was then used as a bacterial barrier, as it was essential to prevent further infection which would increase the risk of having the prosthesis removed.
- A 10cm x 10cm dressing was applied to the wound with a weekly dressing change. This was continued for 3 weeks until almost full epithelialisation was observed (Figure 5).
- This patient was managed as an in-patient throughout.

Case 3

- Fifty year old female who was referred to the Wound Care Service with wound breakdown and sinus formation at the mastectomy site after surgery for breast cancer. Figure 6 shows the wound prior to NPWT.
- NPWT was applied to the wound but discontinued after 3.5 weeks because the surrounding skin became sore (Figure 7).
- Kendall AMD antimicrobial foam dressing was the choice of dressing, because of its bacterial barrier function as well as its ability to effectively absorb exudate. It was also important that the wound continued to progress as the patient required further treatment for cancer.
- A 10cm x 10cm dressing was applied and changed weekly for 5 weeks until full epithelialisation was observed (Figure 8). The patient then was able to start her chemotherapy treatment for the cancer.
- The patient was managed on an out-patient basis

Case 4

- Fifty-six year old female developed necrotising fasciitis and a mucocele following an abdominal hysterectomy.
- She presented with a large abdominal wound to which NPWT was applied.
- After 7 weeks of NPWT, the wound bed was filled with clean healthy granulation tissue.
- Kendall AMD antimicrobial foam dressing was then used, with two 10cm x 20cm dressings applied. The dressing was changed twice weekly.
- The patient was discharged home two weeks after NPWT was applied; the ongoing treatment described above continued on an out-patient basis.

Discussion


Negative pressure wound therapy was used on wounds where there had been extensive tissue breakdown which occurred as a result of infection. As PHMB gauze was used within the system, and none of the wounds developed new infections, it was decided that this course of therapy should be continued within an impregnated dressing (Kendall AMD antimicrobial foam dressing).

Clinicians are never 100% confident that where extensive infection has been present, systemic antibiotic therapy has entirely eliminated the risk of recurrence. With an open wound, there is also the risk of new infections developing, which in the cases presented here would have severe consequences for future treatment, rehabilitation and quality of life.

Kendall AMD antimicrobial foam dressing was observed to perform well as a post NPWT treatment. In these cases, it was applied to clean, granulating wounds, which then progressed well. Although no formal cost calculation was made, the price of the dressing, the frequency of dressing change, and the wound progression without complications are factors worth considering in a future study to evaluate cost-effectiveness.

Conclusion

The PHMB impregnated foam dressing (Kendall AMD antimicrobial foam dressing) is already available within the Wound Care Formulary located in the Doncaster and Bassetlaw NHS Foundation Trust, in addition to other topical antimicrobial agents (silver, iodine and honey). Since there is no known bacterial resistance to PHMB, this dressing is often the first choice when an antimicrobial dressing is required. This evaluation also demonstrates that the PHMB foam dressing performs well as post NPWT treatment.



Presented at EWMA 2010.

This evaluation was sponsored by Tyco Healthcare Group LP d/b/a Covidien, Mansfield, MA, 02048, USA.

™Trademark of a Covidien company