


Medtronic

HawkOne™ Directional Atherectomy System



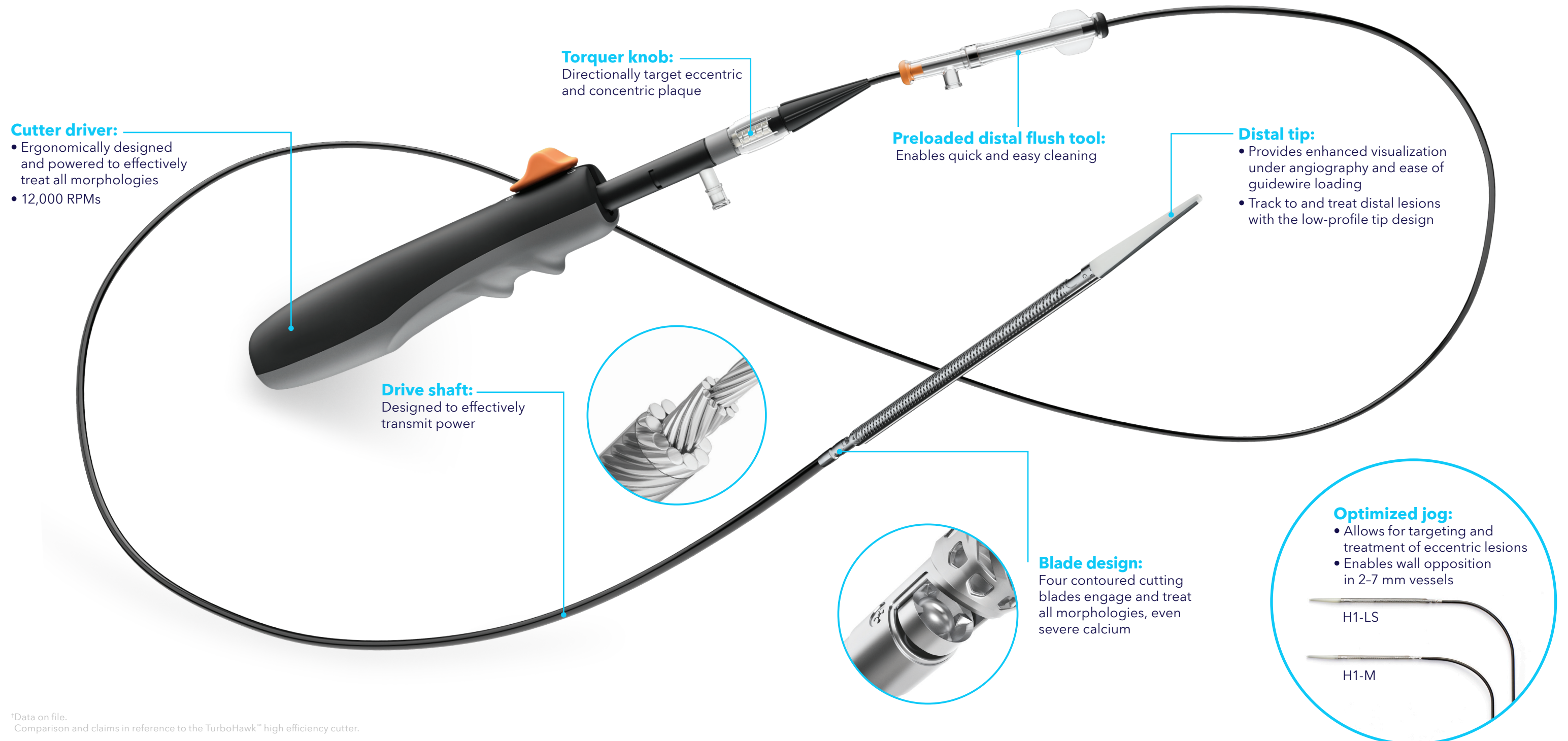
One device
for above
and below
the knee

Treat all morphologies

- Consistent and predictable cutting
- Treats all lesion morphologies, from soft to severely calcified

Treat with procedural efficiency

- Simplified directional atherectomy selection with 6 F and 7 F HawkOne devices
- No capital equipment provides easy setup



[†]Data on file.
Comparison and claims in reference to the TurboHawk™ high efficiency cutter.

Versatility above and below the knee

The HawkOne platform offers control and enhanced cutting to target and debulk all morphologies to gain lumen, prepare the vessel, and treat calcified lesions.



HawkOne directional atherectomy system¹⁻⁵

| Treatment goal | Lesion morphology | Plaque distribution |
|--------------------|----------------------|---------------------------|
| Achieve lumen gain | Treat severe calcium | Target eccentric lesions |
| Create a channel | Treat soft plaque | Target concentric lesions |

| | Model name | Catalog number | Vessel diameter (mm) | Sheath compatibility (Fr) | Crossing profile (mm) | Working length [†] | Effective length [‡] | Tip length (cm) | Max. cut length (mm) | Packing device |
|-----|------------|----------------|----------------------|---------------------------|-----------------------|-----------------------------|-------------------------------|-----------------|----------------------|----------------|
| 7 F | LS | H1-LS | 3.5-7.0 | 7 | 2.6 | 114 | 107 | 6.6 | 50 | ● |
| | LX | H1-LX | 3.5-7.0 | 7 | 2.6 | 114 | 104 | 9.6 | 75 | ● |
| 6 F | M | H1-M | 3.0-7.0 | 6 | 2.2 | 135 | 129 | 5.9 | 40 | ● |
| | S | H1-S | 2.0-4.0 | 6 | 2.2 | 151 | 145 | 5.9 | 40 | ● |

Max guidewire is 0.014" for HawkOne devices.

[†]HawkOne working length – distal end of pre-loaded flush tool, in the proximal position, to the distal end of tip.

[‡]HawkOne effective length – end of pre-loaded flush tool, in the proximal position, to the proximal end of cutter window.

¹ Aboufakher R, Torey J, Szpunar S, Davis T. Peripheral plaque volume changes pre- and post-rotational atherectomy followed by directional plaque excision: assessment by intravascular ultrasound and virtual histology. *J Invasive Cardiol.* October 2009;21(10):501-505.

² McKinsey J, Zellar T, Rocha-Singh KJ, Jaff MR, Garcia LA, DEFINITIVE LE Investigators. Lower extremity revascularization using directional atherectomy: 12-month prospective results of the DEFINITIVE LE study. *JACC Cardiovasc Interv.* August 2014;7(8):923-933.

³ Roberts D, Niazi K, Miller W, et al. Effective endovascular treatment of calcified femoropopliteal disease with directional atherectomy and distal embolic protection: final results of the DEFINITIVE Ca++ trial. *Catheter Cardiovasc Interv.* August 1, 2014;84(2):236-244.

⁴ Bench data on file.

⁵ See Instructions for Use.

Important information

For a listing of indications, contraindications, precautions, warnings, and potential adverse events, please refer to the Instructions for Use.

Medtronic

medtronic.ca

©2023 Medtronic. All rights reserved. Medtronic, Medtronic logo and Engineering the extraordinary are trademarks of Medtronic. [™]Third party brands are trademarks of their respective owners. All other brands are trademarks of a Medtronic company. UC202302042 EC CA-IVR-0063-E Rev. 01/2023