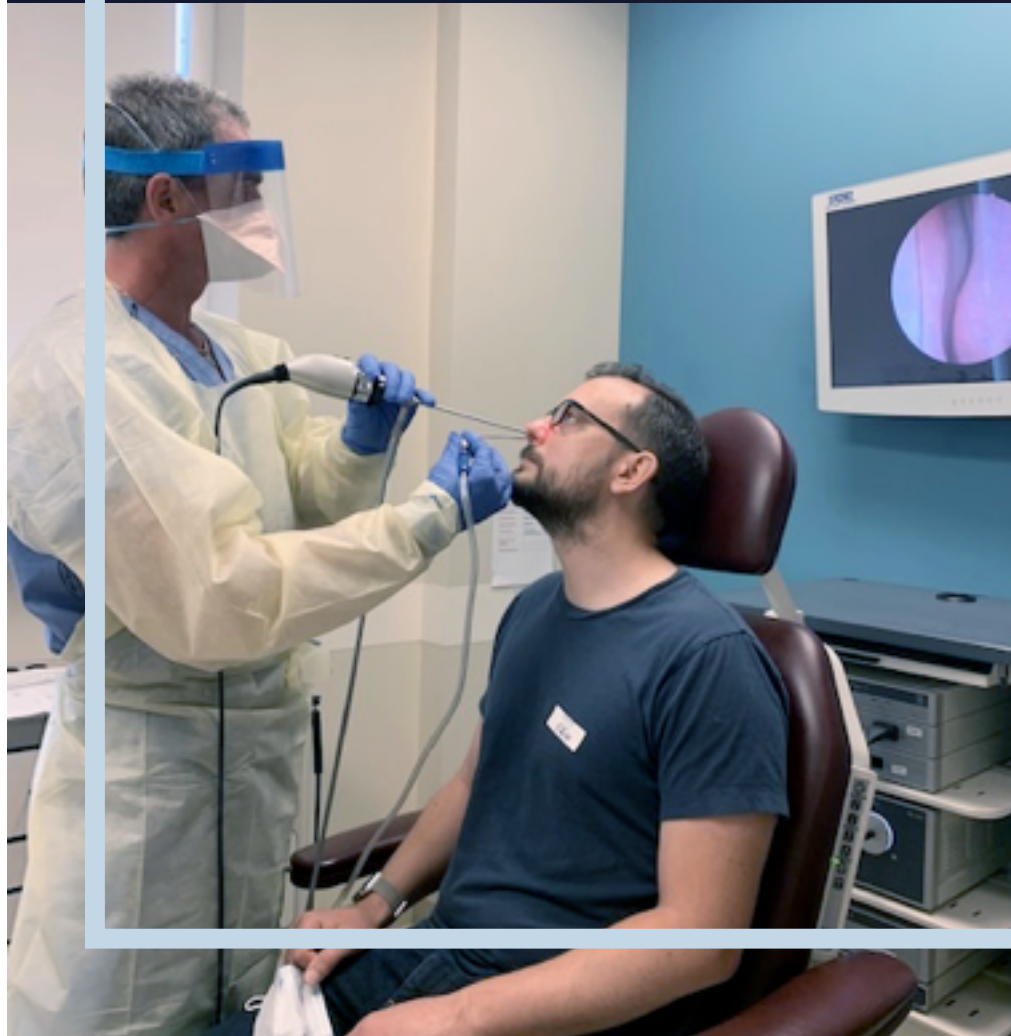

OFFICE-BASED RHINOLOGIC SURGERY

MEDICAL EDUCATION



John M. DelGaudio, MD, FACS, FARS

Vice Chair

Professor of Otolaryngology

Chief of Rhinology and Skull Base Surgery

Director Emory Sinus, Nasal & Allergy Center

Emory University

Medtronic
Further. Together

PREFACE

This eBook is part of a series focused on relevant surgical techniques of modern Rhinology.

The series will help ENT physicians explore increasing medical advances in this exciting area by presenting trending surgeries by experienced medical professionals from around the world. Dr. DelGaudio is being paid by Medtronic for his authorship of this eBook in accordance with applicable laws and regulations.

This eBook is being made available for general educational purposes only and is being provided to surgeons looking for a deeper understanding of office-based rhinologic procedures. It should not be considered the exclusive source for this type of information.

NOTA BENE

The office-based techniques described herein and the instructions for the related procedures are made available to the healthcare professional to illustrate the author's suggested treatment for the appropriate patient. The content has been provided by Dr. DelGaudio and the positions and opinions of Dr. DelGaudio are his own and based on his professional clinical judgement. Medtronic does not take a position on matters of clinical practice outside the scope of the safe and effective use of its products.

In the final analysis, the preferred treatment is that which, in the healthcare professional's clinical judgment, addresses the needs of the individual.

Each practitioner should practice within their own comfort zone.



PROLOGUE

The goal of office-based surgical procedures should be the same as if the procedure was performed in the operating room. The difference in location should not result in a difference in outcome.

If the same result can not be achieved in the office setting, then the procedure should be performed in the operating room. Always give the patient the option of surgery in the operating room.

At all times, it is the professional responsibility of the practitioner to exercise independent clinical judgment in a particular situation.

John DelGaudio

ENT-otolaryngologist Atlanta, Georgia

How to use the Book

The book provides you with helpful additional information.

Don't just read it, experience it, unlock the full potential by exploring the additional information beside the icons.



Interact



More information



Enlarge



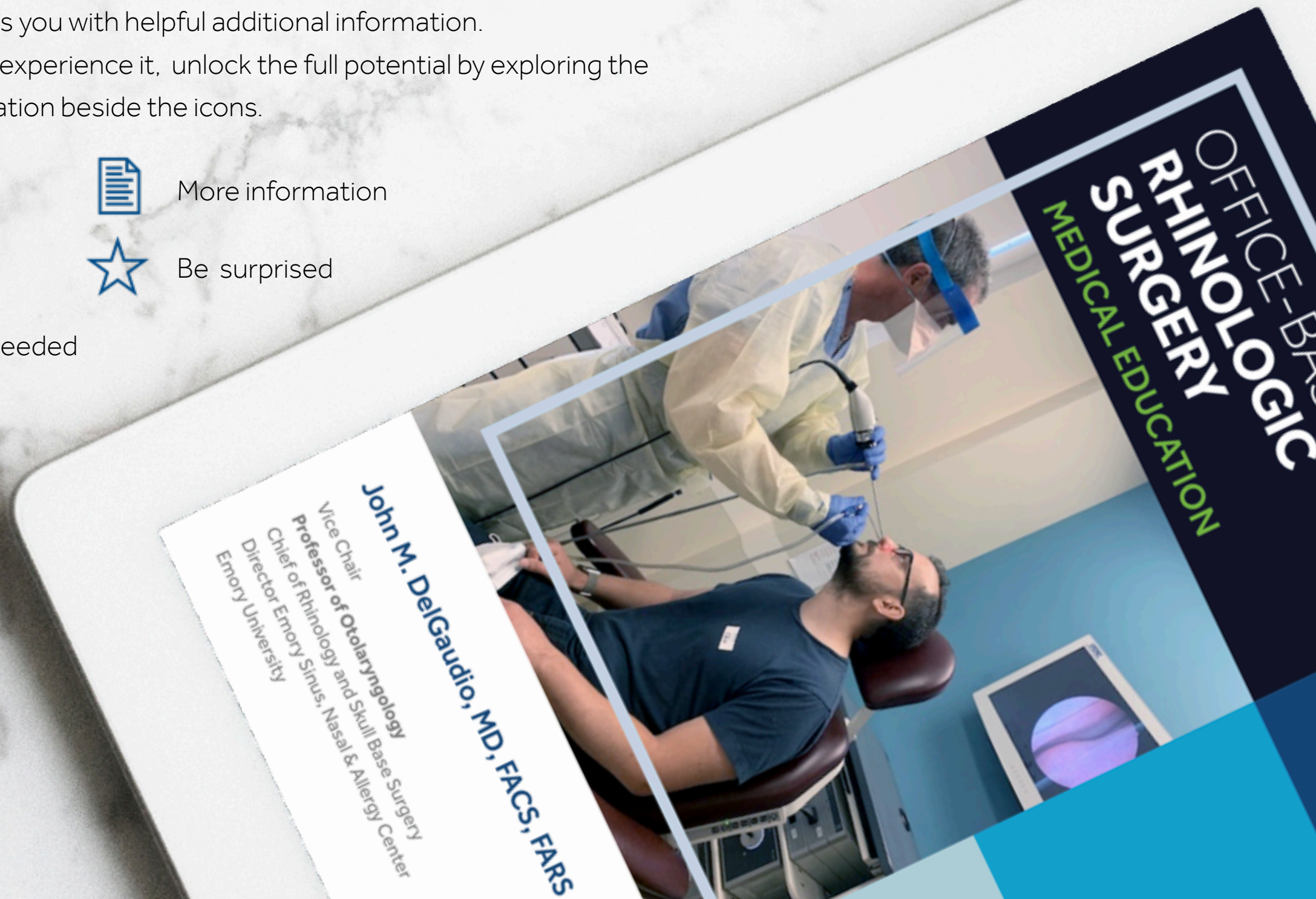
Be surprised



Internet needed



Watch



CONTENTS

Introduction

- Trends
- Advantages
- Informed consent
- Equipment, setup, & patient positioning
- Patient selection
- Contraindications

Anesthesia

- What & how

Pathologies & Procedures

- Inferior turbinate hypertrophy
- Sinus recirculation
- Polypectomy
- Fungus ball
- Acute & chronic rhinosinusitis
- Mucocele
- Masses

Post Procedure Care

- Follow-up & Conclusions

Post Procedure Care

- Special considerations Covid 19
- References



INTRODUCTION

Trends

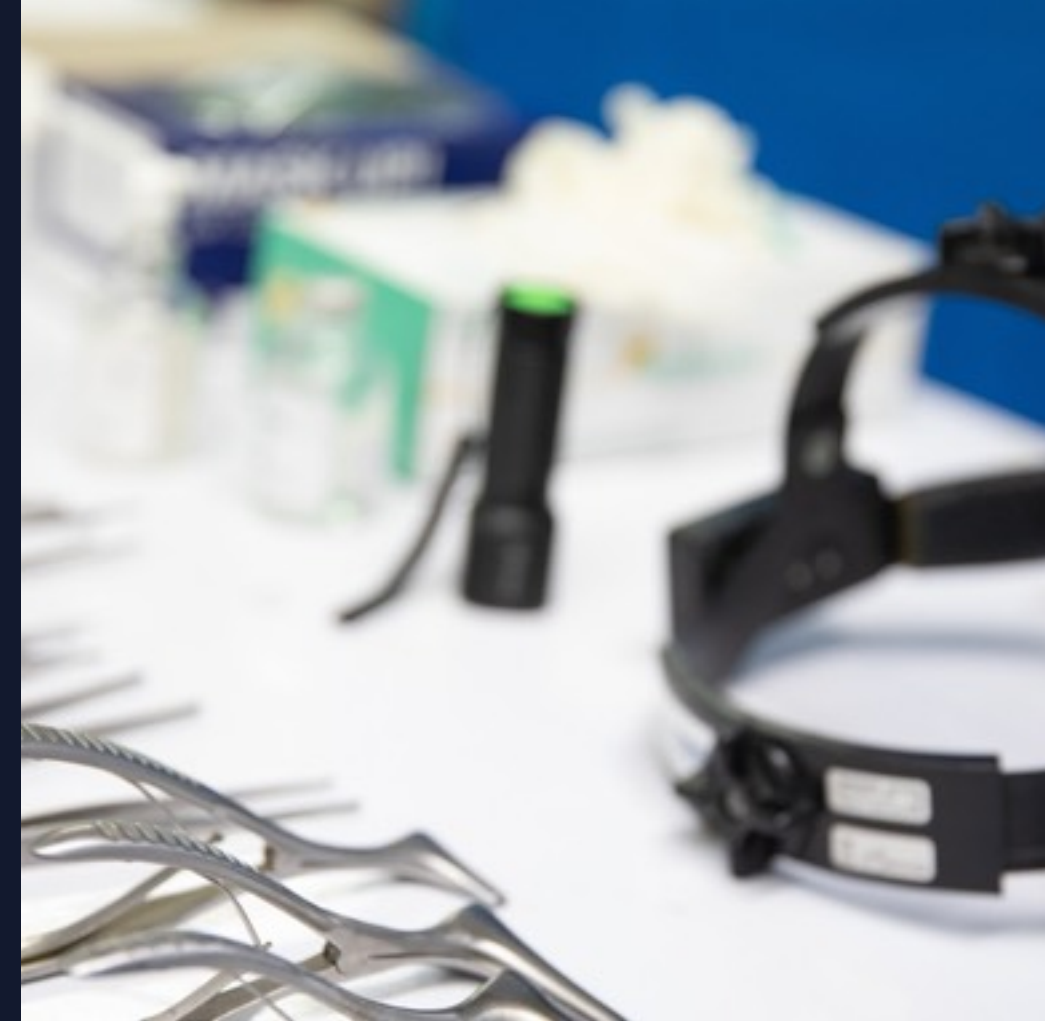Advantages

Informed consent

Equipment & setup

Patient selection

Indications &
contraindications



A trend^{1,2}

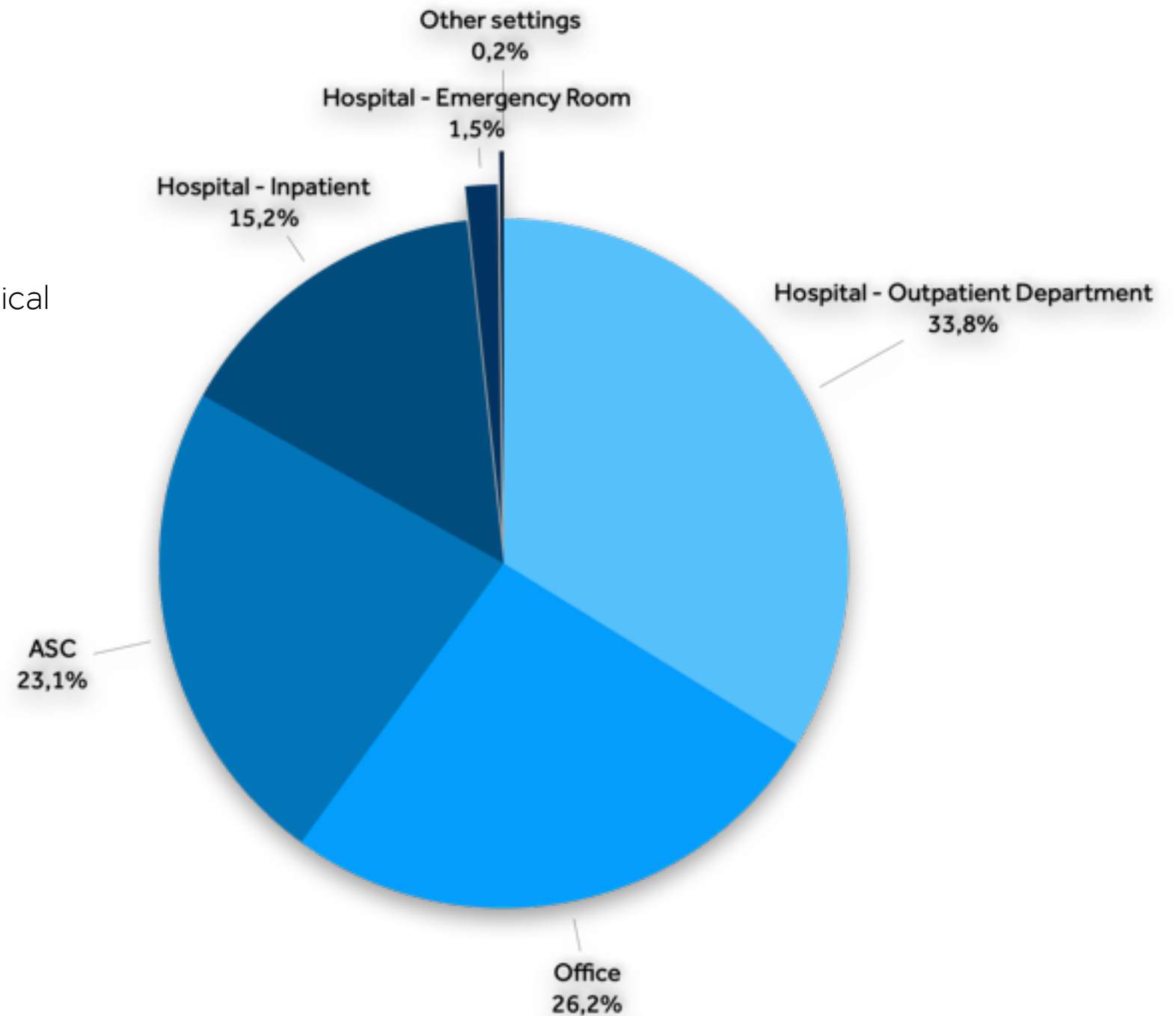
More time is being spent in the office setting and less in the operating room setting. This trend is coinciding with the increase in office-based surgical procedures. In some areas, such as the USA, there are significant advantages to performing office procedures compared to operating room procedures for both the physician and the patient.

The original ESS surgeons used IV sedation and topical/local anesthesia for their surgical procedures in the operating room. Adapting this to the office is a natural progression of office endoscopy and debridement, which most rhinologic surgeons already perform.

A survey of the members of the American Rhinologic Society confirmed a significant increase in office-based procedures¹.

- 157 respondents - 11.9%
- 41% academic, 59% private practice
- 99% performed office procedures
- Debridements - 99%
- Polypectomy - 77%
- Balloon dilation - 56%
- 63% confirmed increased office procedures in past 5 years

A survey of the membership of the American Academy of Otolaryngology- Head and Neck Surgery showed that the vast majority of surgical procedures were being performed in the ambulatory setting, including the office.



Source:

AMERICAN ACADEMY OF OTOLARYNGOLOGY-
HEAD AND NECK SURGERY
13TH SOCIOECONOMIC SURVEY MAY 2014



Click

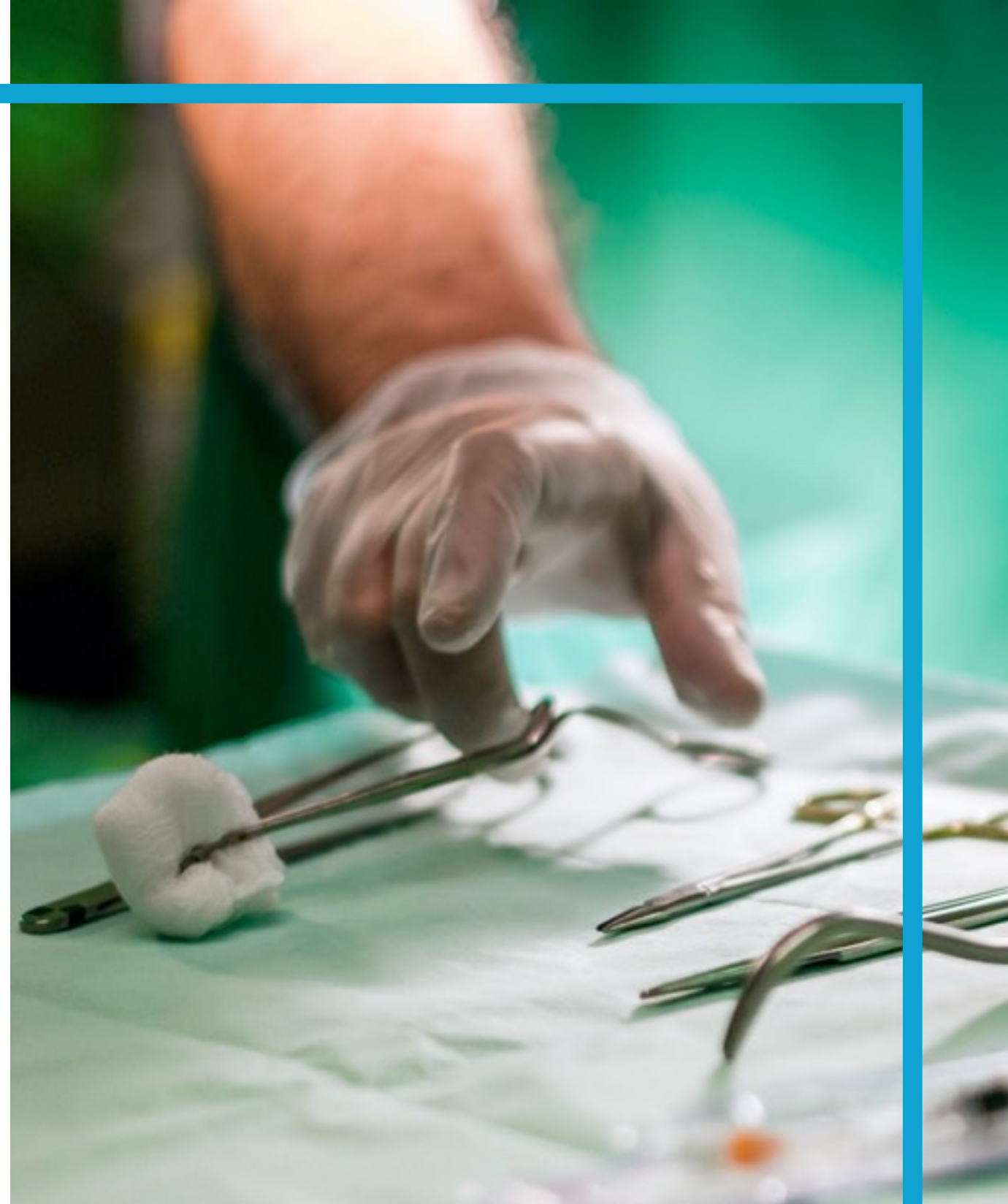
Advantages²

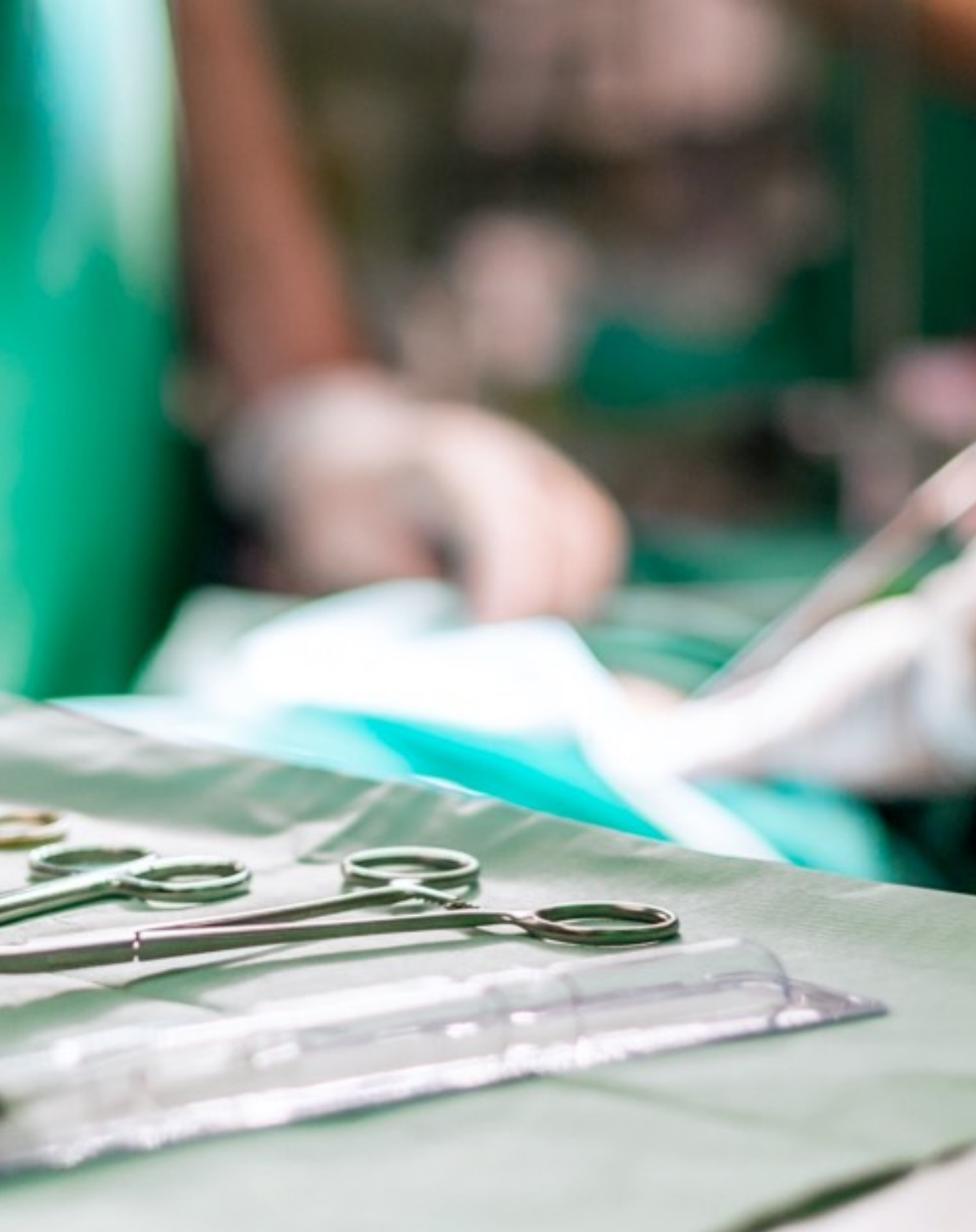There are many advantages of office-based rhinologic surgery for the physician and patient.

There is no need for operating room time or general anesthesia. This results in a much shorter recovery period than for general anesthetic procedures.

Patient satisfaction is very high for patients undergoing office-based surgery.

Office-based surgery has a lower overall cost to the healthcare system due to the lack of operating room and anesthesia charges, less facility fees, and less patient absenteeism.





Cost analysis of office-based and operating room Procedures in Rhinology³

In appropriate patients, performing rhinologic procedures in the office offers savings of at least \$3.300-\$5.000 per procedure to the healthcare system. The difference is less if there is a facility fee charged*.

Performing rhinologic procedures in the office does not adversely affect physician reimbursement*.

There is very high patient satisfaction with office procedures. If they had to do it again, most patients would choose an office-based procedure over an OR procedure.

*This reflects the situation at the US healthcare market.

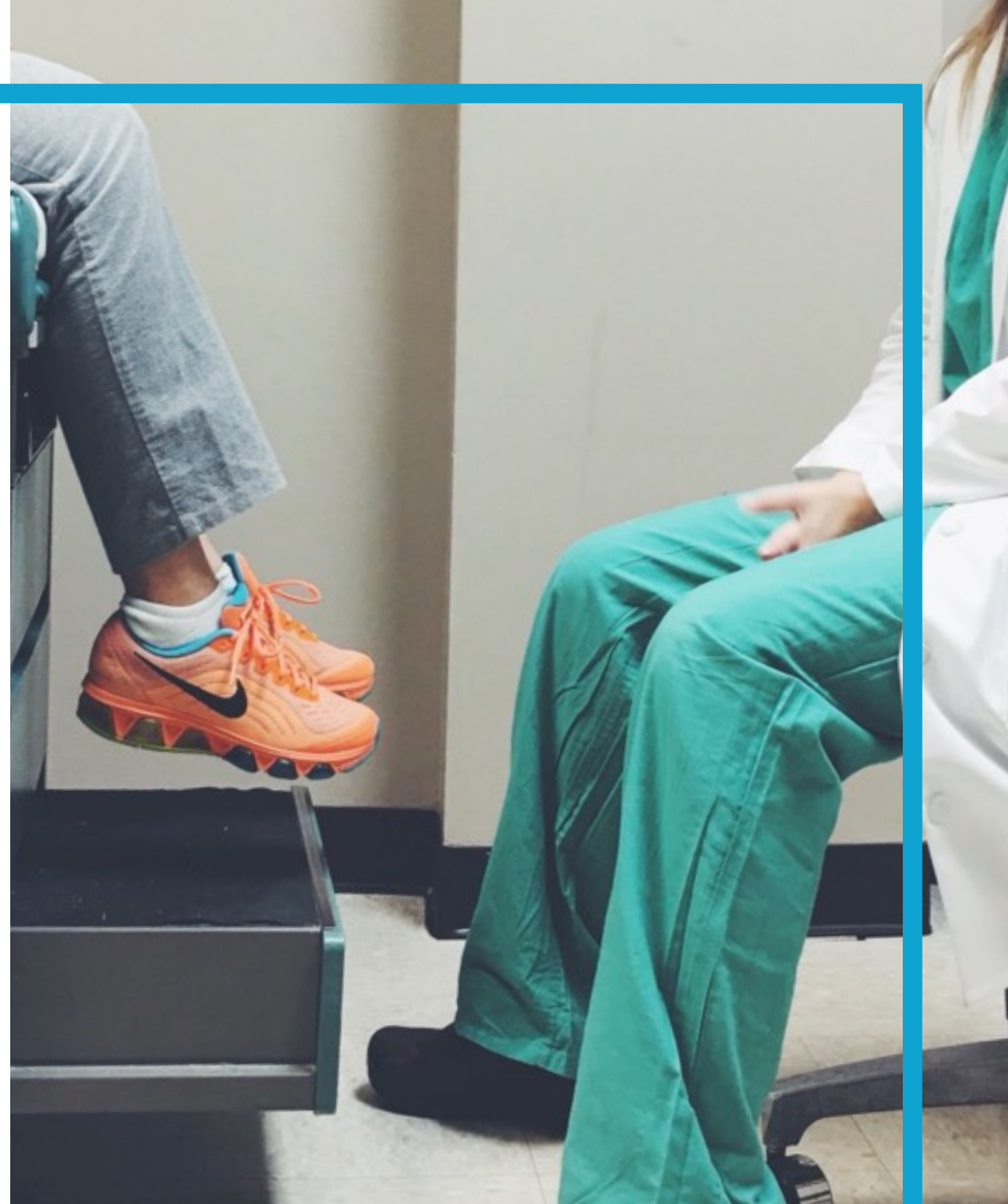Informed consent

All patients undergoing office-based surgery should undergo the informed consent process.

Office-based rhinologic procedures carry similar risks to OR procedures, and the informed consent discussion should be the same as for a procedure performed in the operating room.

Elements that should be included in the informed consent discussion:

- Explanation of the planned procedure
- Discussion of alternatives to office surgery
- The risks and benefits of the procedure

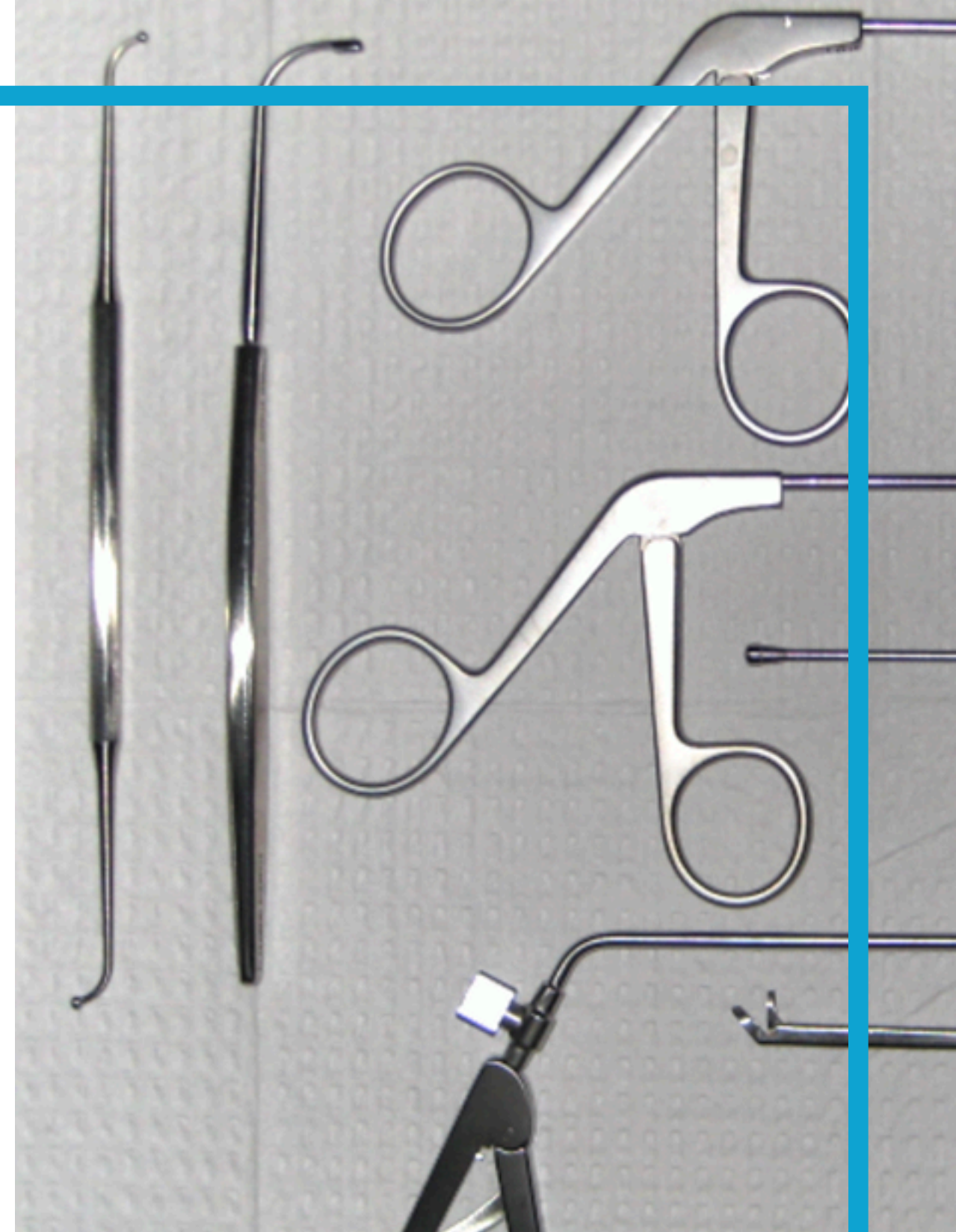


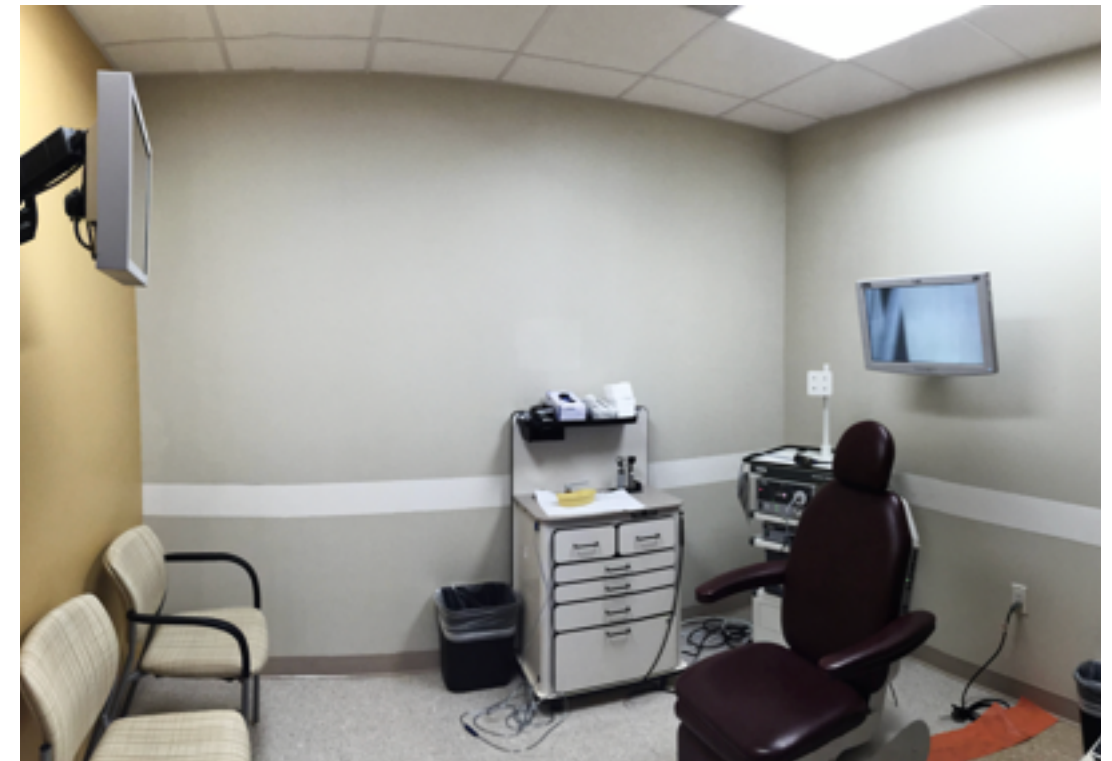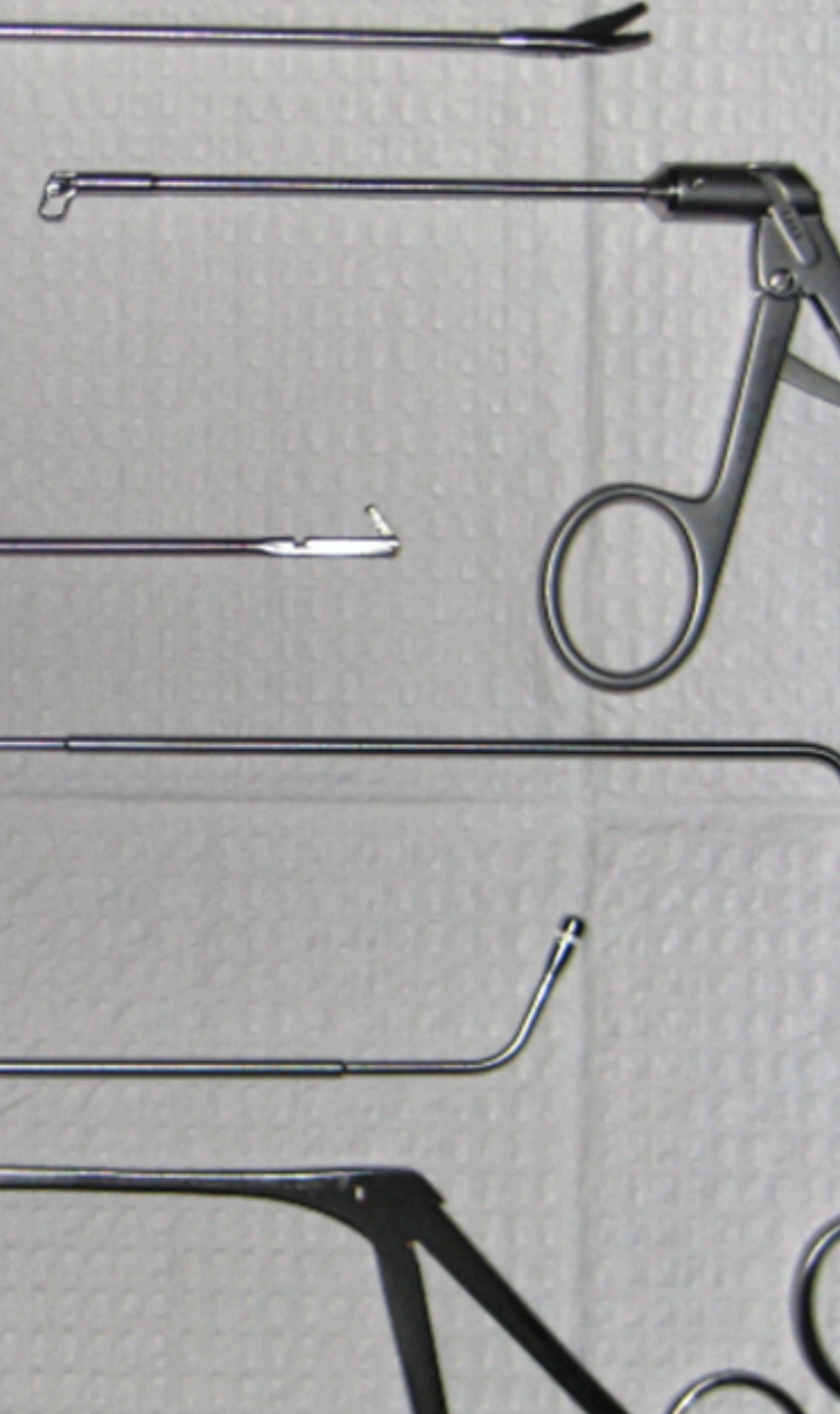
Equipment, setup, & patient positioning

The **instrumentation** available should be comparable to what is available in the operating room, and will vary by procedure. These should include:

- Full set of sinus surgery instruments
- Microdebrider/tissue shaver
- Radiofrequency device or similar
- Cautery
- Sinus Ostial Balloon dilation system

The patient should be positioned in a slightly reclined position with the head slightly tilted back. The headrest needs to be adjusted so that the patient can comfortably maintain this position for the duration of the procedure.





High-Definition video system with multiple monitors, so that the patient can view the procedure. This is both anxiety relieving and educational for the patient. Video documentation device for recording the procedure.

Office rhinologic surgery procedures are performed with the **patient in the seated position**, with a very slight recline. The surgeon can be seated or standing, depending on preference. This position prevents engorgement of the tissue that can occur with the recumbent position. It also reduces the amount of blood that may trickle into the nasopharynx.

Patient selection

Patient selection is critical. Anxious patients may not make good office surgery candidates. Completely explain the procedure and talk the patient through the procedure. This may alleviate anxiety in patients.

Patients who are high-risk for general anesthetic may still be candidates for office surgery. Always give the patient the option to have the procedure in the operating room. Giving the patient the option makes them part of the decision making process and may also alleviate some anxiety about the office procedure.



Relative Contraindications

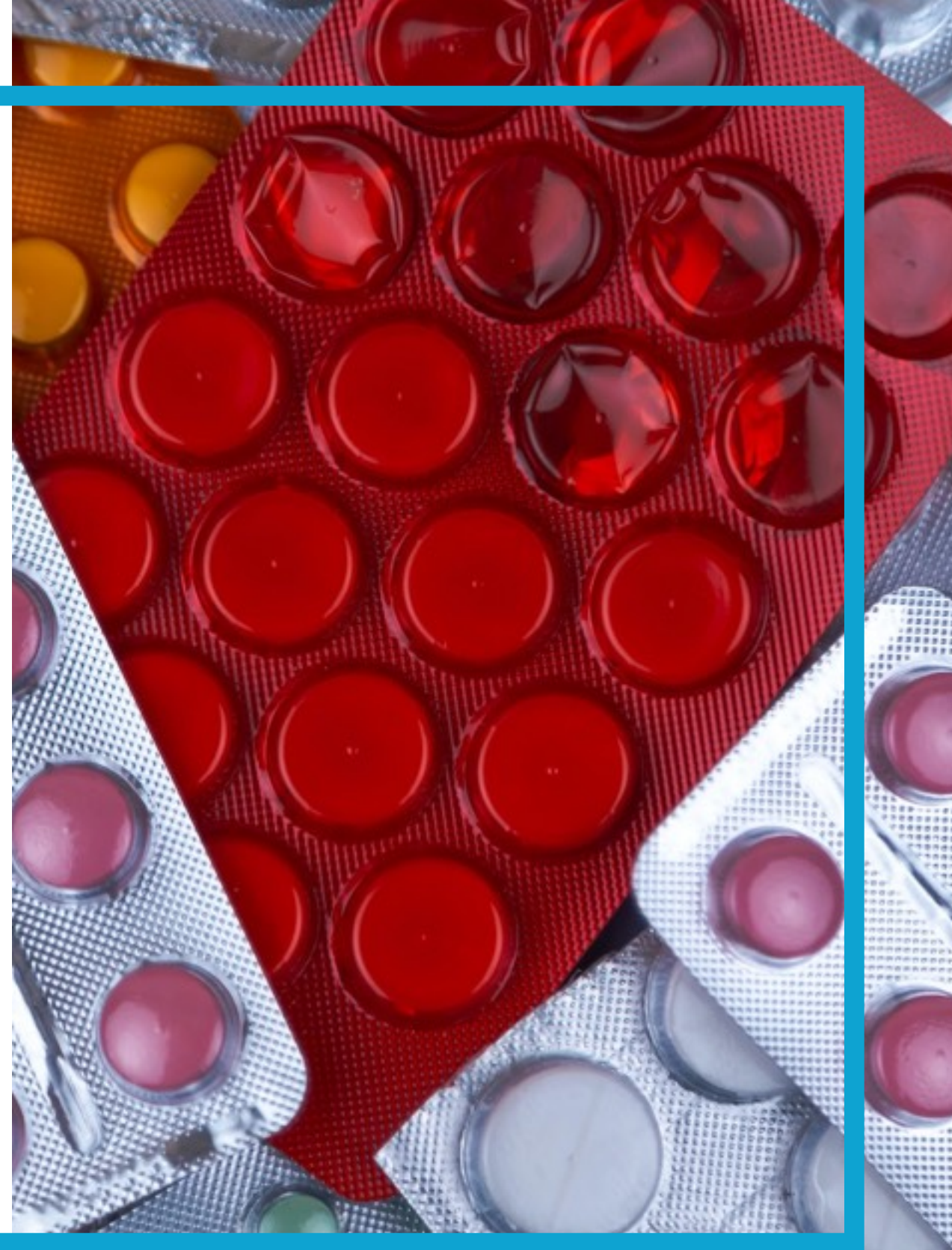
There are two aspects to consider when not to operate in an office-based setting.

Patient factors

- Very anxious patient
- Bleeding disorder/anticoagulant use
- Poorly controlled hypertension
- Severe cardiac disease

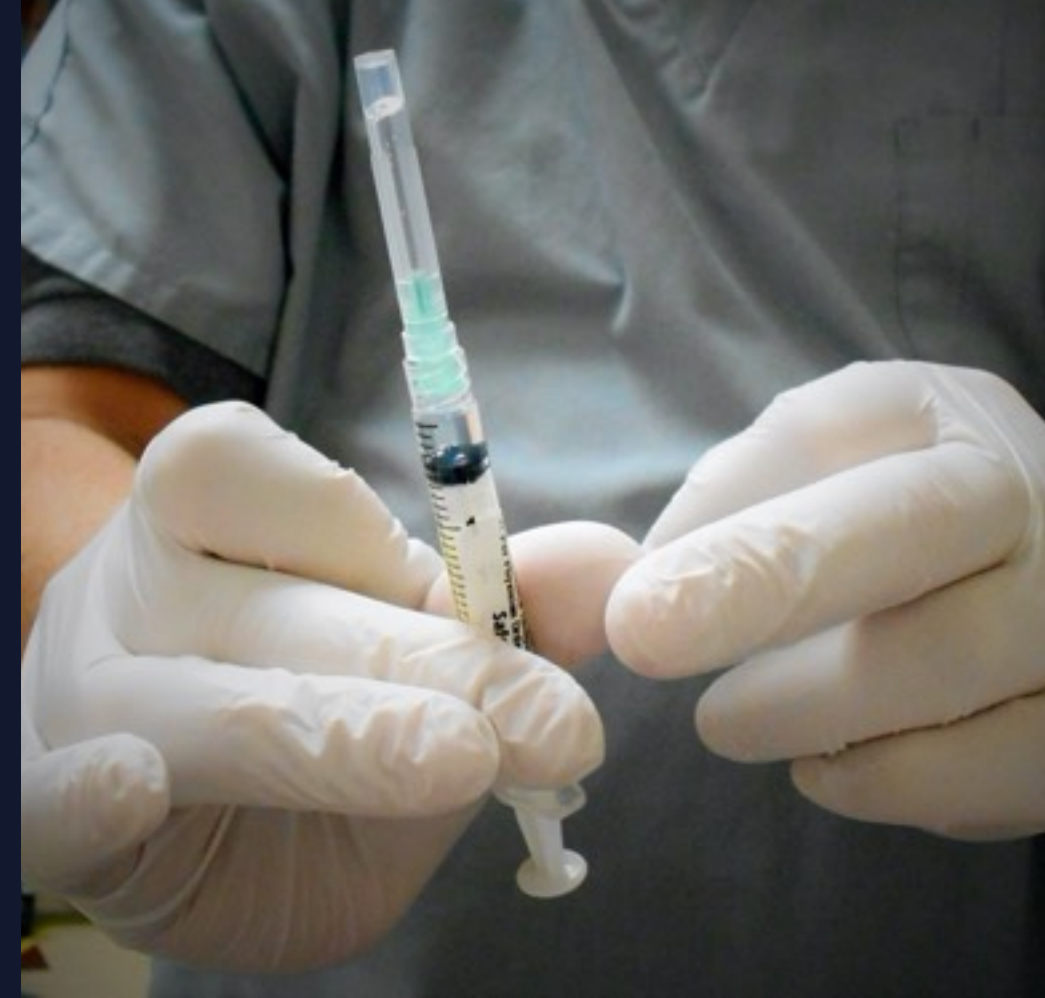Pathology factors

- Significant deviation of the nasal septum, with poor access to the pathology
- Extensive pathology beyond the scope of office-based surgery
- Large, highly vascular lesions



ANESTHESIA

What & how

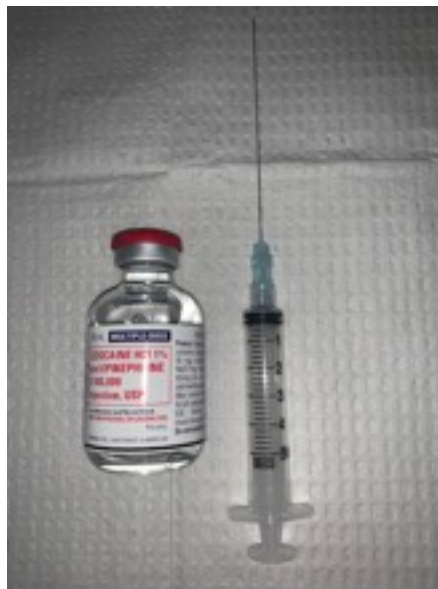

Medtronic
Further, Together

What & how

Adequate anesthesia is critical

Topical lidocaine (4%) and oxymetazoline or neosynephrine is normally used. Other combinations can also be effective. Submucosal injection of 1% lidocaine with 1:100,000 epinephrine can be used if necessary. Reapply anesthesia as needed. The area to be injected will depend on where the procedure is being performed.

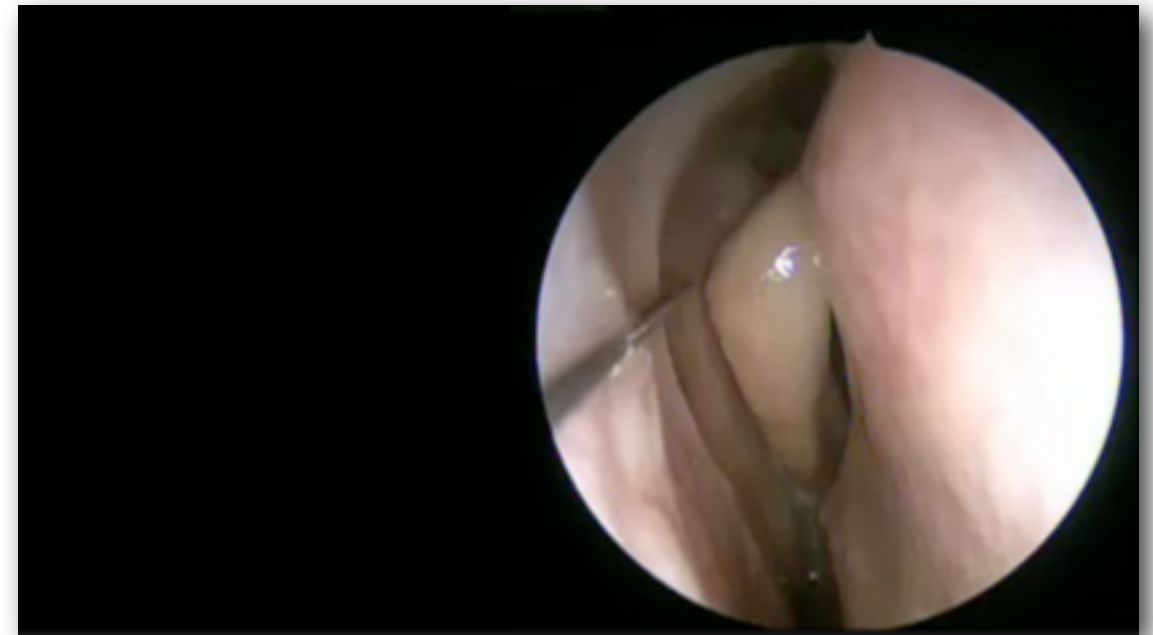


Nerve blocks (usually not necessary)

Greater palatine block

Sedation (usually not necessary)

If sedation is utilized, then the patient should have O₂ saturation monitored.



This video demonstrates injection of the uncinate process and middle turbinate in preparation for a maxillary antrostomy to evacuate a fungus ball. The middle turbinate is anesthetized because it will be medialized and undergo repeated contact with the instrumentation, which could otherwise cause discomfort.

PATHOLOGIES & PROCEDURES

Inferior turbinate hypertrophy

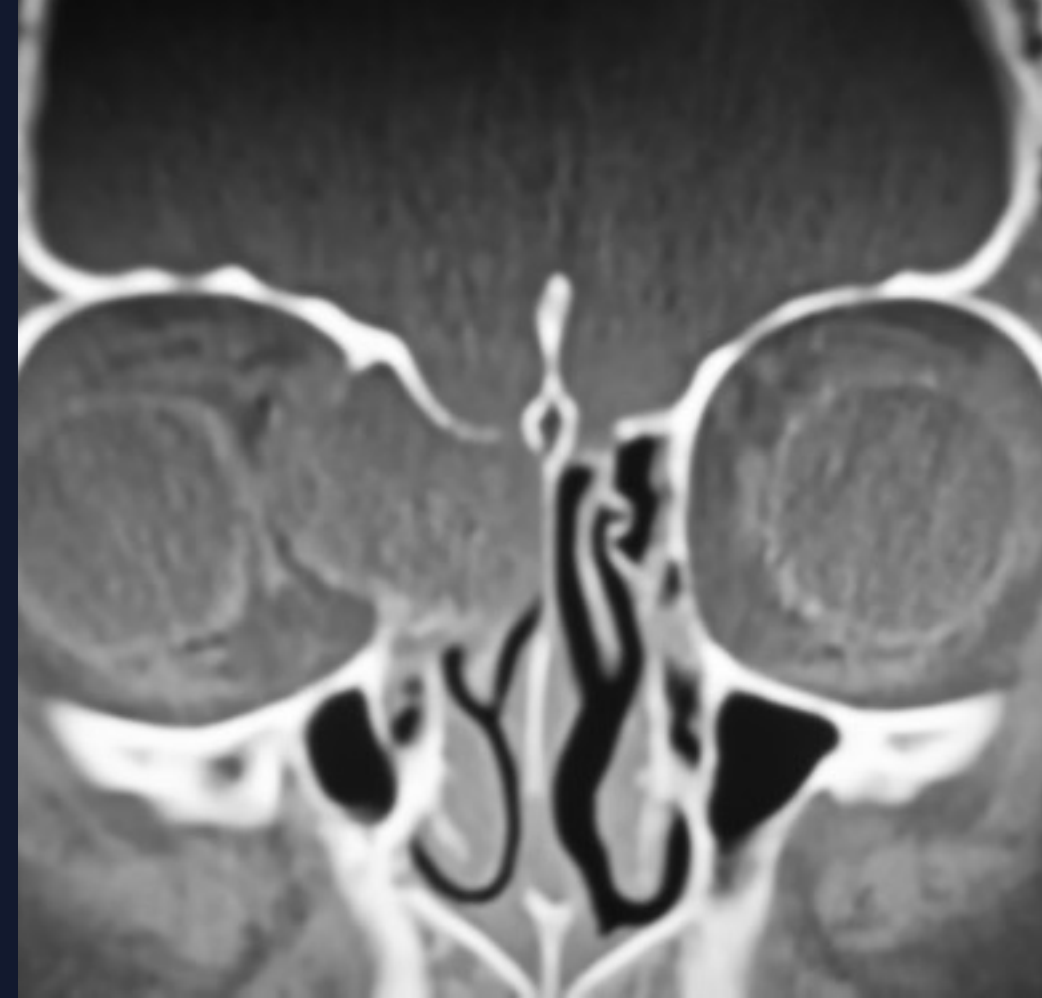
Sinus recirculation

Polypectomy

Fungus ball & chronic rhinosinusitis

Mucocele

Masses

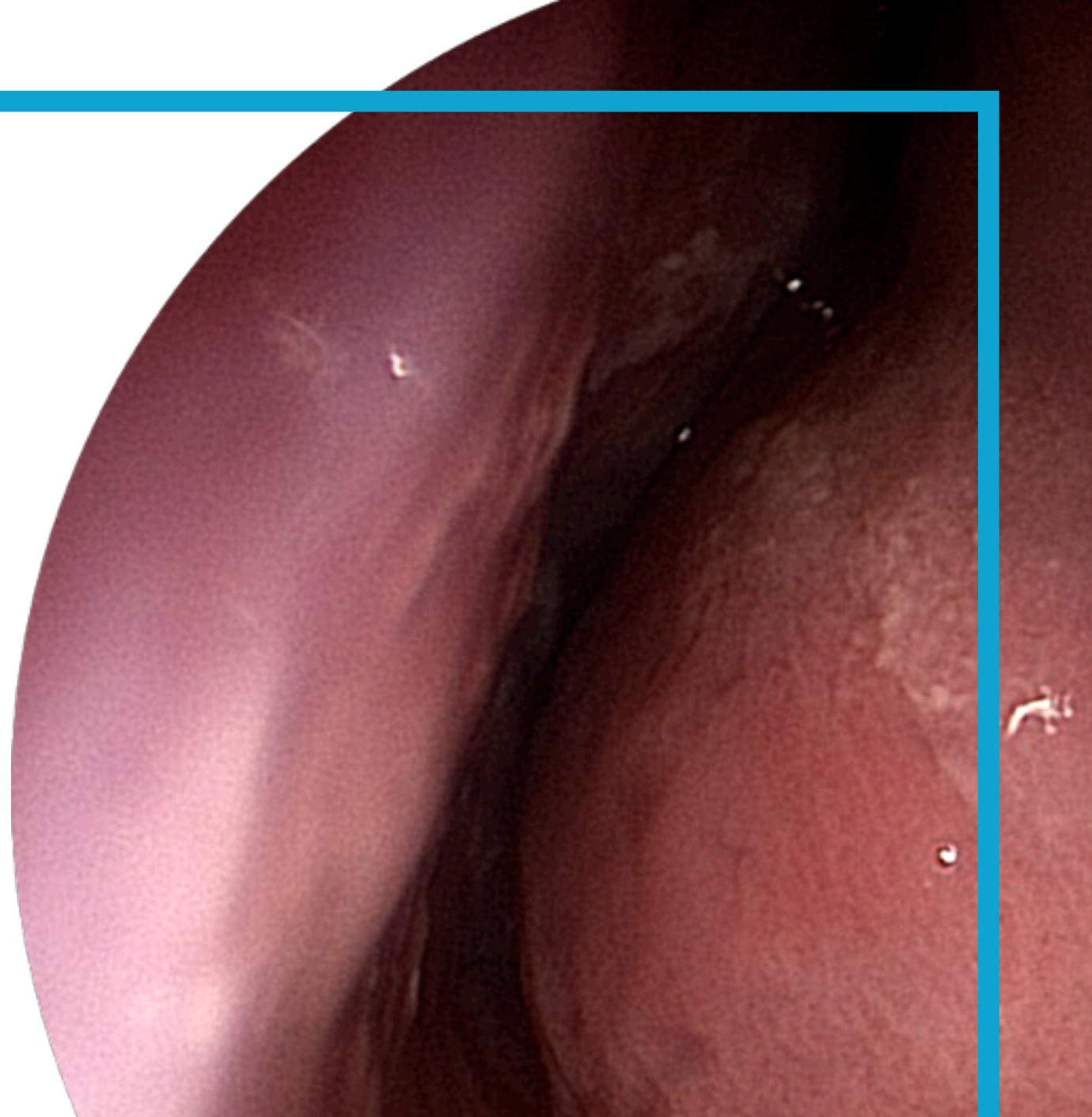


Inferior Turbinate Hypertrophy

Answer the question & check your answer

Office inferior turbinate reduction procedures are best suited for patients with:

- ☐ A. A deviated nasal septum
- ☐ B. A deviated nasal septum and hypertrophy of the inferior turbinates
- ☐ C. Chronic rhinosinusitis
- ☒ D. Recumbent engorgement of the inferior turbinates



Click

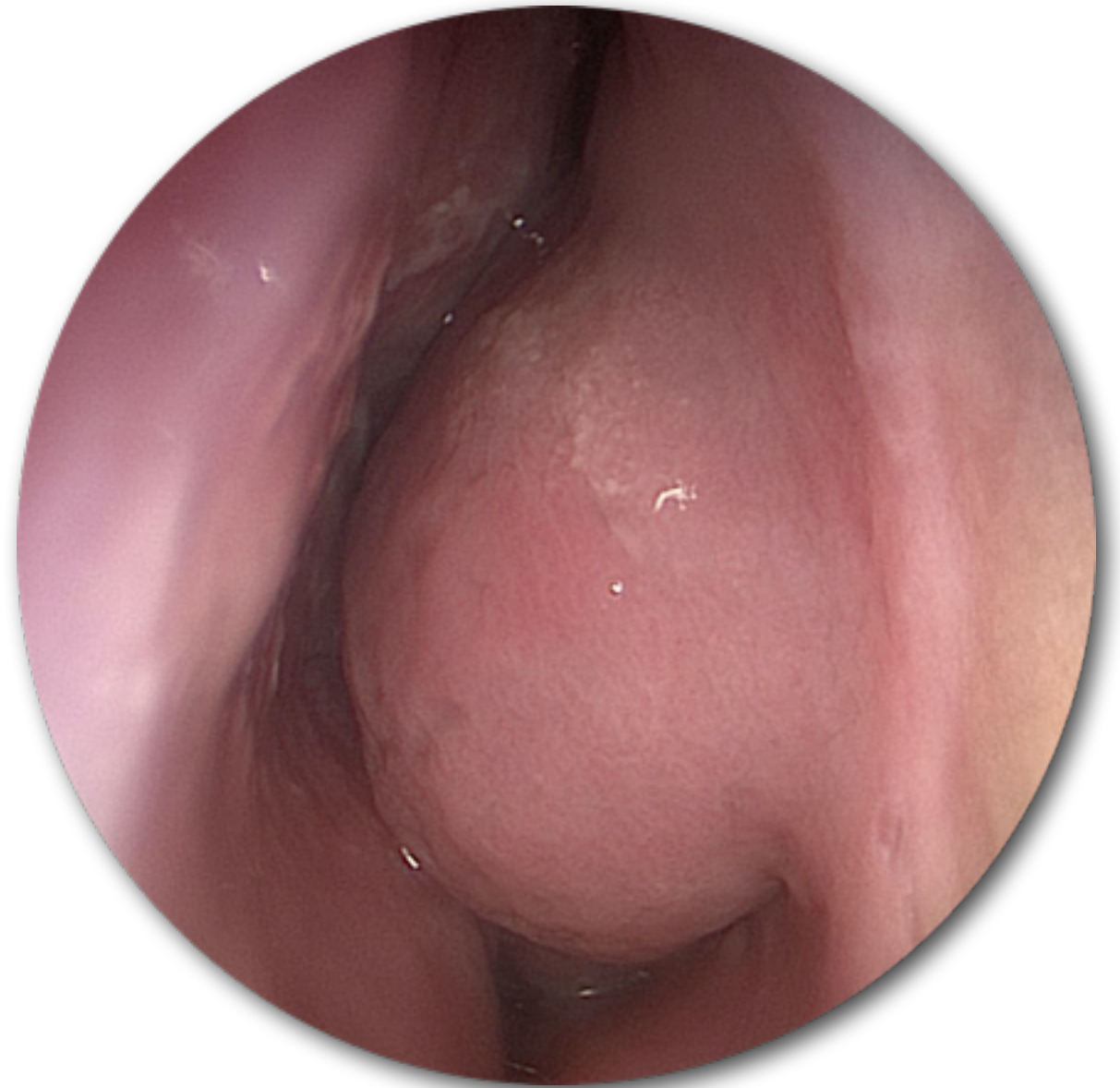
Check Answer

Medtronic
Further, Together

Pathology

The inferior turbinates can become hypertrophied as a result of inflammation, allergy, or infection.

The nasal cycle becomes less frequent with age, resulting in loss of elasticity of the tissue. This can result in dependent engorgement of the inferior turbinates when the patient is lying down, frequently affecting the dependent side and changing with positional changes. This is the ideal patient for office inferior turbinate reduction.



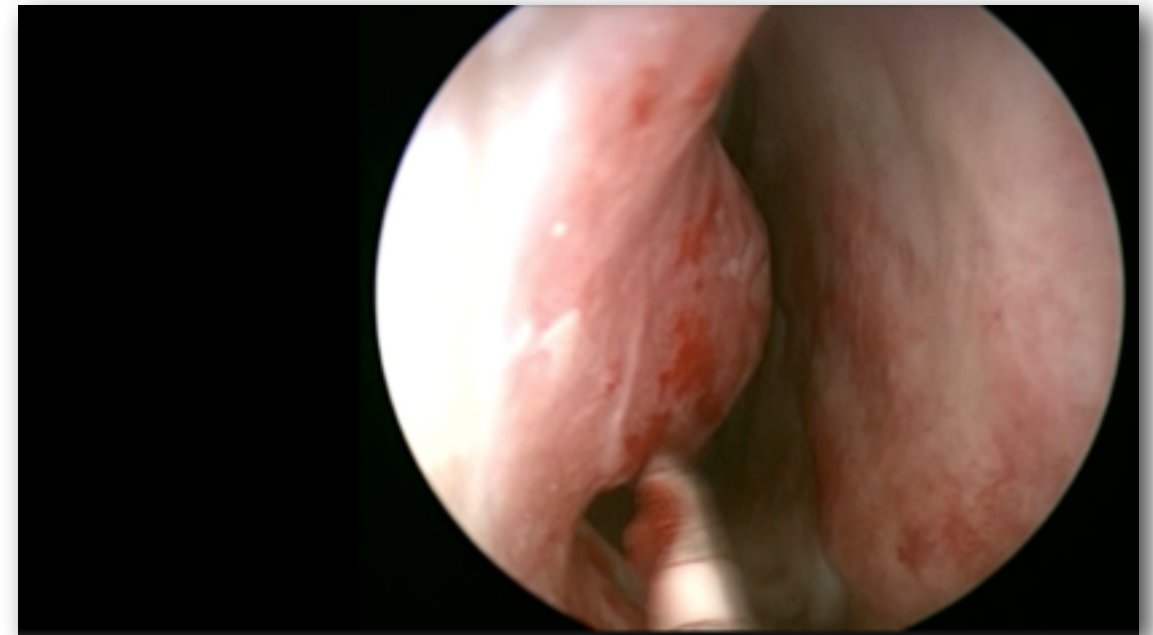Inferior Turbinate Radiofrequency Reduction

Inferior turbinate reduction can be performed in the office with radiofrequency when the septum does not need to be addressed or a patient does not want to undergo septal correction surgery. This procedure results in replacement of the submucosal vascular tissue with fibrosis (non-vascular), thereby reducing the volume of the inferior turbinate that can become engorged. This procedure is very well tolerated by patients.

Postoperative care requires moisturization of the nasal mucosa with frequent application of saline spray.

After several days of post-procedural nasal congestion, improved nasal breathing should occur within a week after the procedure.

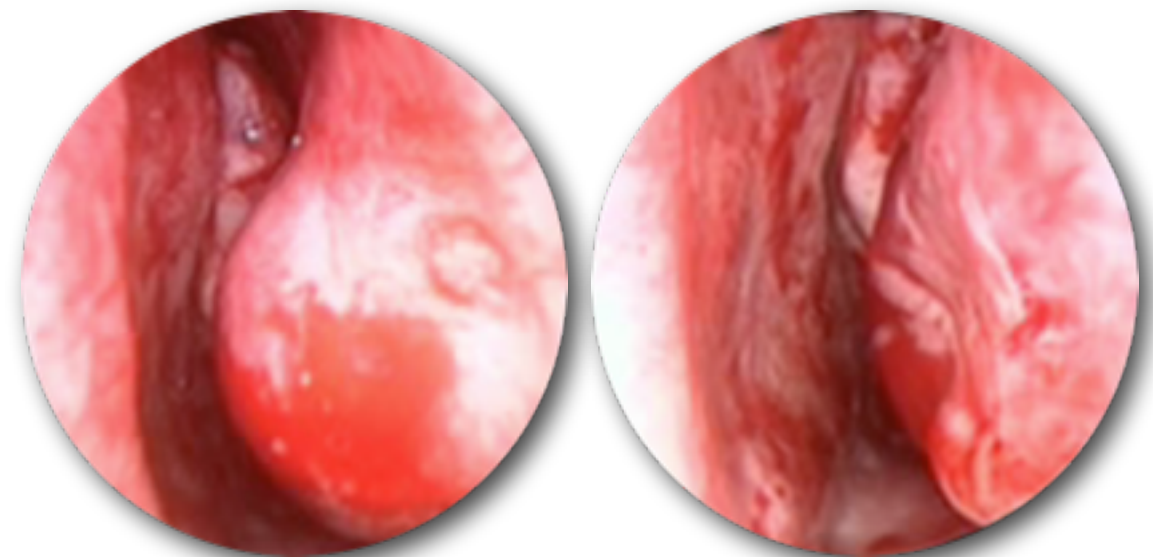
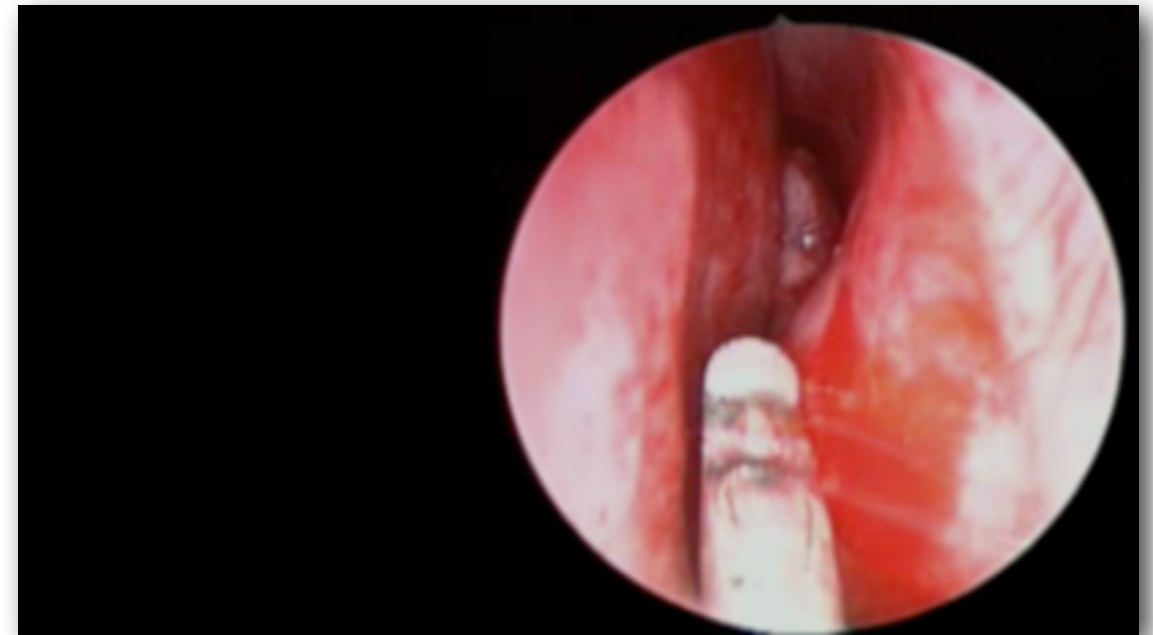
Occasionally a minor debridement of the inferior turbinate may be necessary about three to four weeks after the procedure.



Inferior Turbinate Submucosal Reduction with Turbinate Blade

Inferior turbinate reduction can be performed in the office with the submucosal inferior turbinate blade when the septum is not a contributing factor to the nasal obstruction or a patient does not want to undergo septal correction surgery. This procedure resects the submucosal vascular tissue while preserving the mucosa, thus reducing the volume of the inferior turbinate by "sculpting". This procedure is very well tolerated by patients.

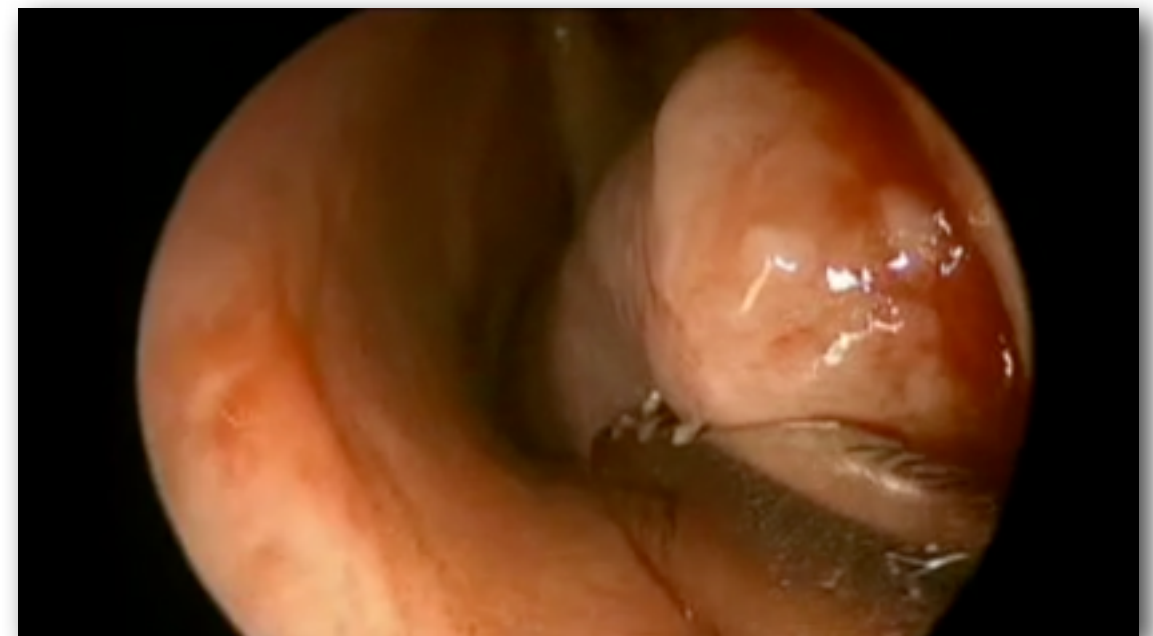
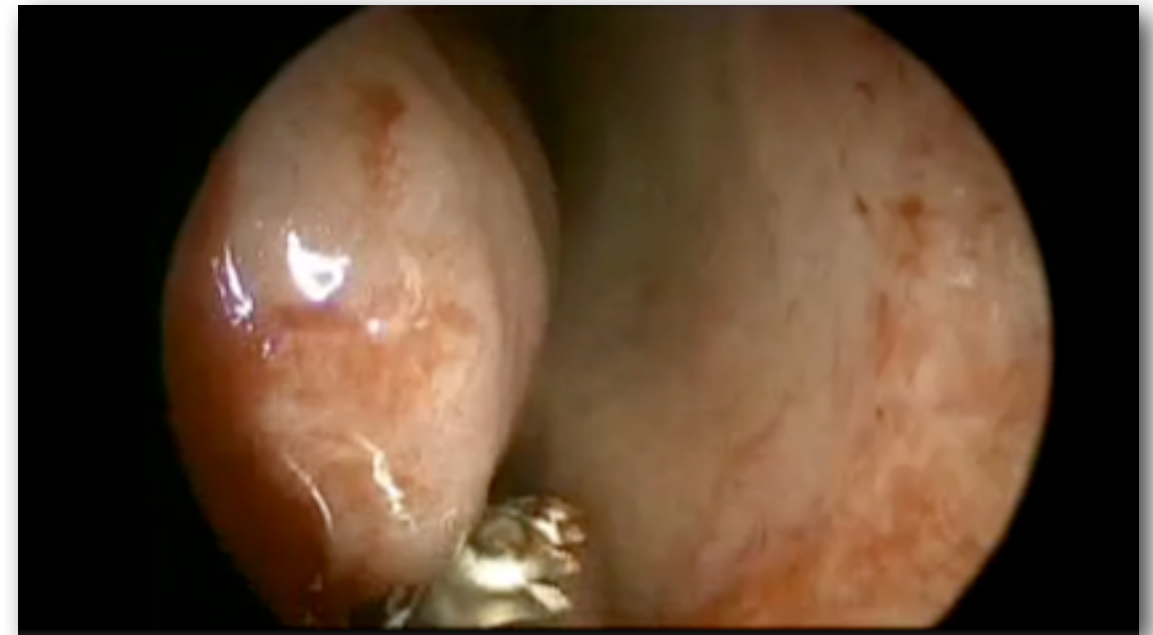
After making a stab incision in the leading edge of the inferior turbinate, the blade is used to make a submucosal tunnel. Submucosal "sculpting" is performed on the anterior one-third to one-half of the inferior turbinate, first with the blade opening pointed laterally, and then medially to debulk the underside of the mucosa. This reduces the volume of vascular tissue of the inferior turbinate while preserving the mucosa.



Microdebrider Inferior Turbinate Resection for Polypoid Inferior Turbinates

Rarely in cases of severe allergic rhinitis, the inferior turbinates can undergo polypoid degeneration.

This is an example in a 28-year-old professional athlete with bilateral nasal obstruction and significant perennial allergy history. He has failed topical medical therapy and requests a procedure for improvement in symptoms. Physical exam shows polypoid degeneration of the inferior turbinates bilaterally. In this case, submucosal sculpting or radiofrequency reduction would give a less satisfactory result than conservative trimming of the inferior turbinates in the office, as is demonstrated here. A 4 mm cutting blade is used to remove the polypoid mucosa without exposing the bone. The procedure is done bilaterally. This results in a much improved nasal airway. Note the significant polypoid consistency of the inferior turbinates as they are "sculpted".

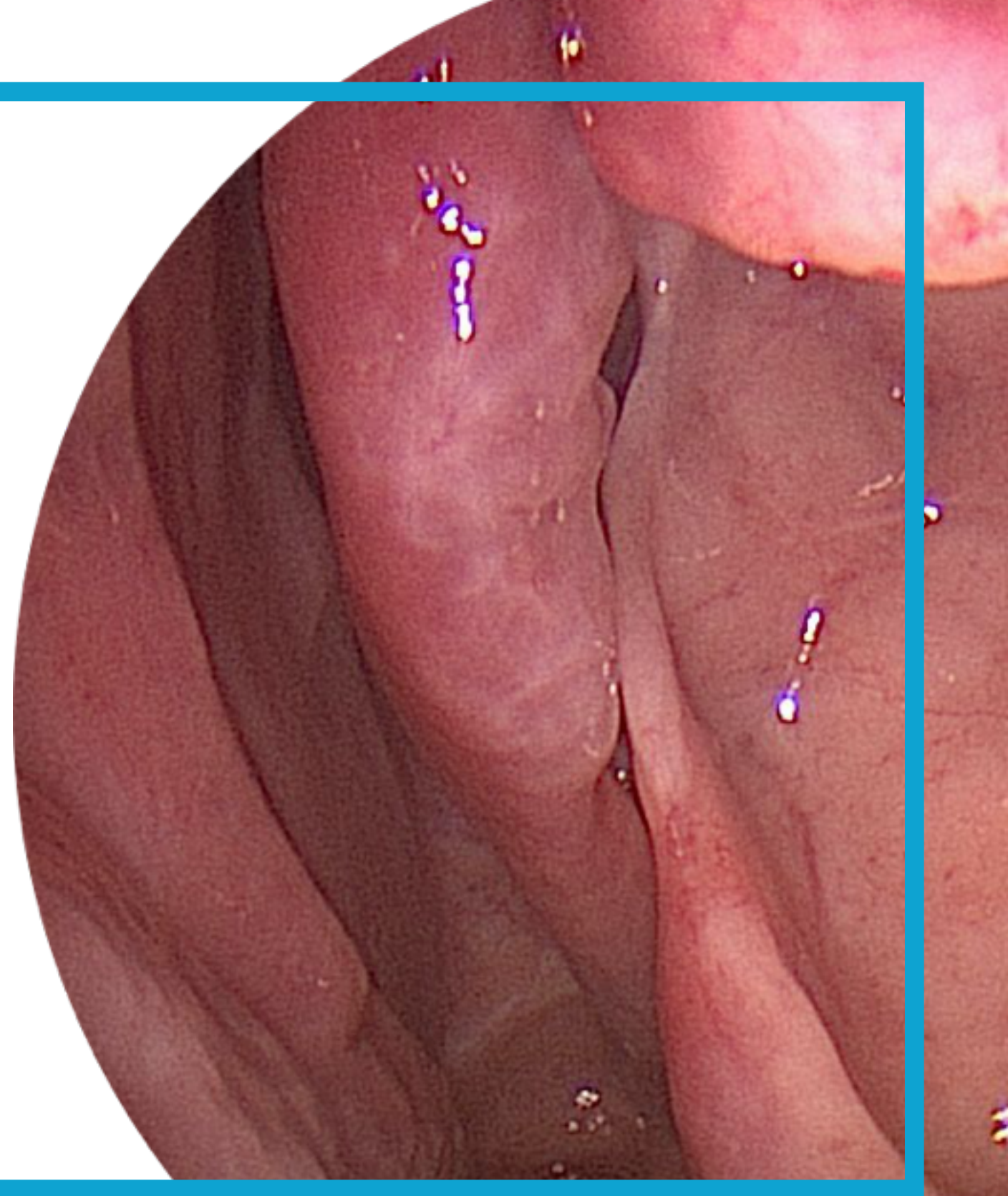


Sinus Recirculation

Answer the question & check your answer

Sinus recirculation is a condition that is most commonly found in:

- ☐ A. Patients with medical refractory chronic rhinosinusitis
- ☐ B. Patients with an anterior and/or posterior fontanelle
- ☒ C. Patients that have had previous sinus surgery
- ☐ D. Patients with no history of chronic rhinosinusitis

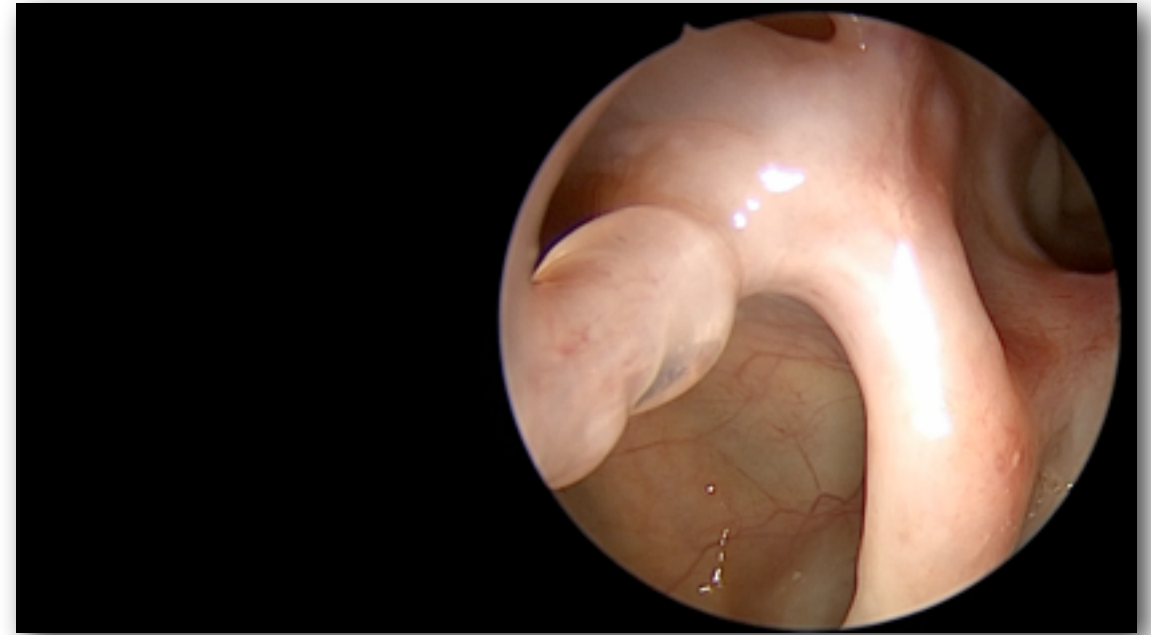


Check Answer

Office Surgery for Paranasal Sinus Recirculation⁴

Sinus recirculation results from abnormal circular flow of mucus between two or more ostia due to normal directional mucociliary flow. This most commonly occurs as a result of endoscopic sinus surgery, when the surgeon fails to connect the surgical maxillary antrostomy to the natural ostium. This results in mucus circulating around the intervening bridge of tissue. This video shows recirculation around a mucosal bridge. Notice a small black particle in the mucus that is moving in a clockwise fashion out of the natural ostium and into the surgical ostium. This phenomenon can cause a feeling of pressure, excessive mucus, congestion, and recurrent/chronic infection, even when the sinus mucosa appears healthy.

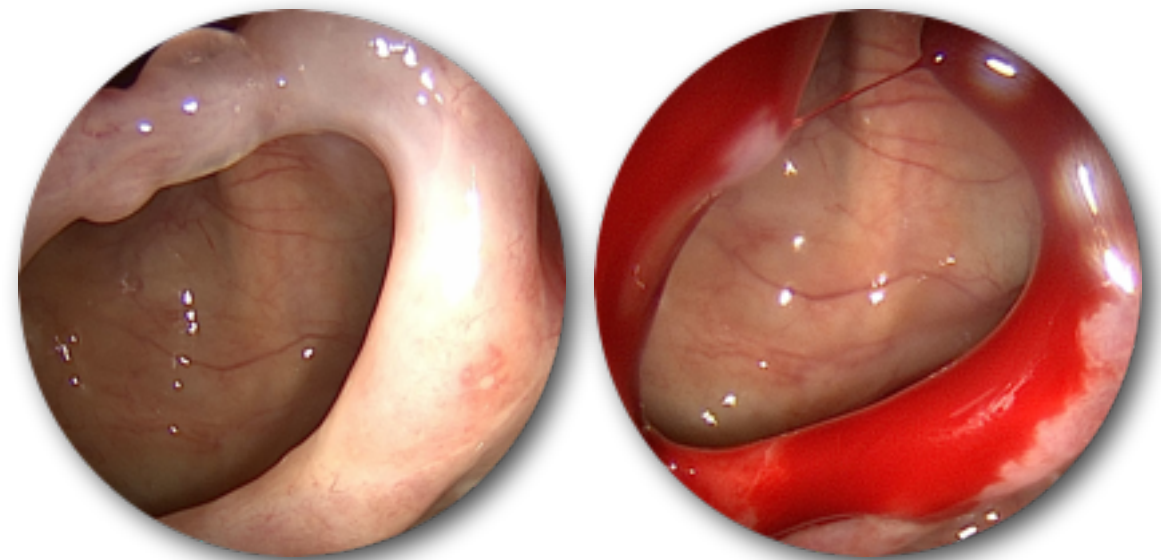
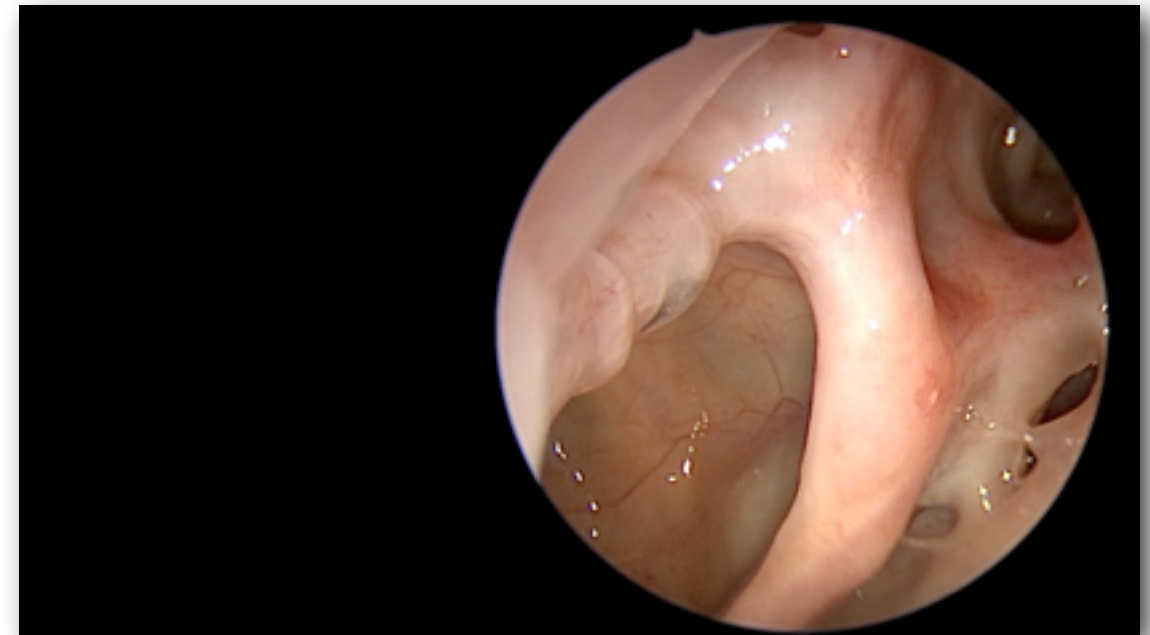
This is very common after ESS, although it does not always cause symptoms.



Maxillary Recirculation

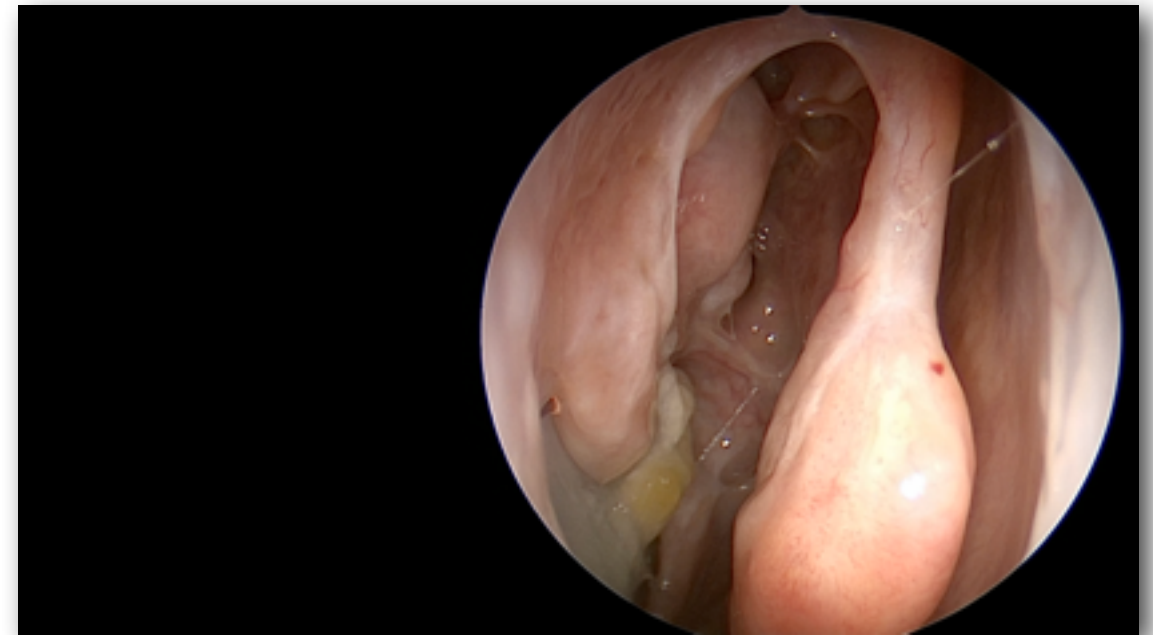
Resection of Mucosal Bridge

The treatment for recirculation is to create a common ostium by removing the intervening bridge of mucosa and bone (if present). This can be done with topical and local anesthetic, as demonstrated in this video.



Case

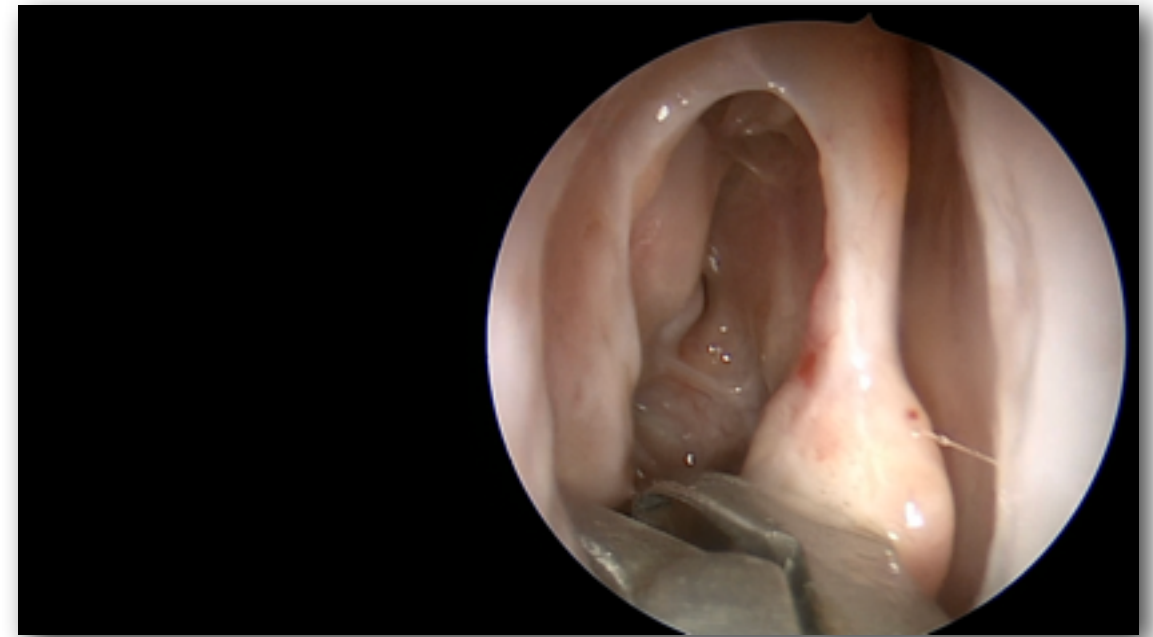
This patient had undergone ESS 2-years prior. Since that time he had recurrent sinus infections, excess mucus, nasal congestion, and right maxillary pressure. He was treated with many courses of oral and IV antibiotics without long-term improvement. On presentation he had obvious recirculation of the right maxillary sinus with infected mucus.



Procedure 1

Office surgery was performed to resect the tissue between the two ostia to create a common ostium and eliminate recirculation.

The patient had complete resolution of his symptoms.



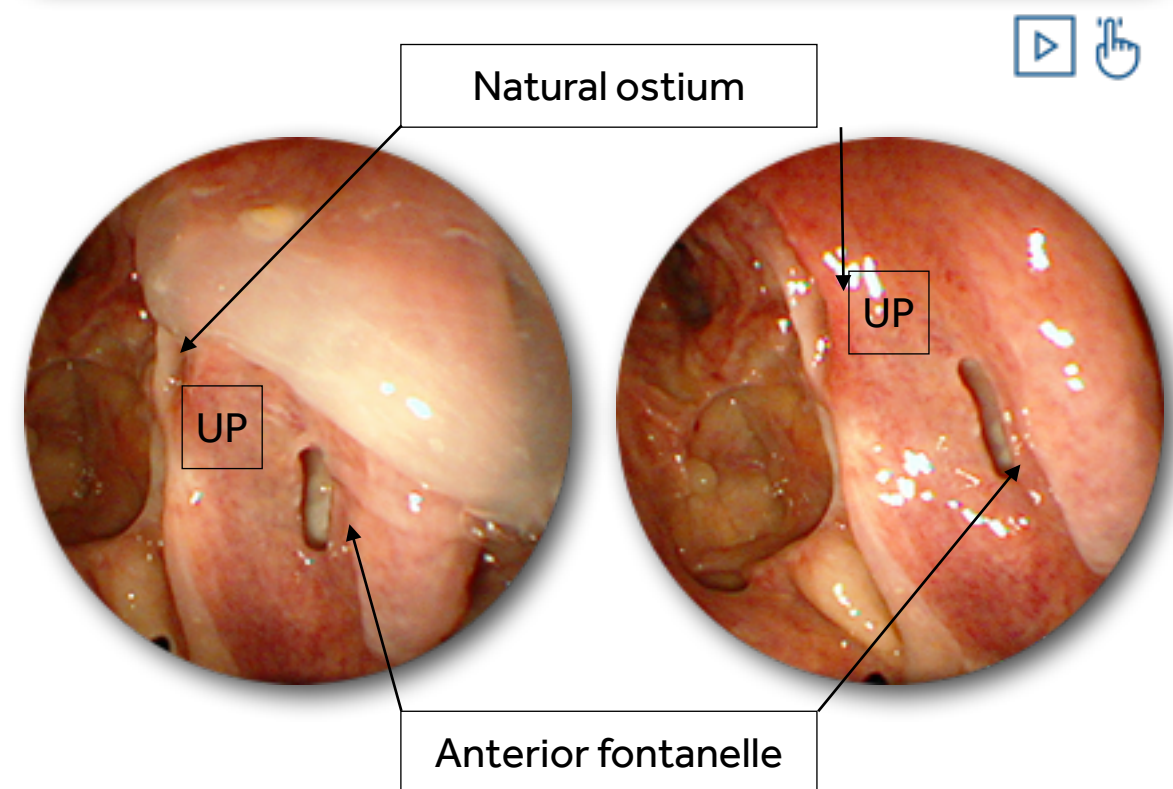
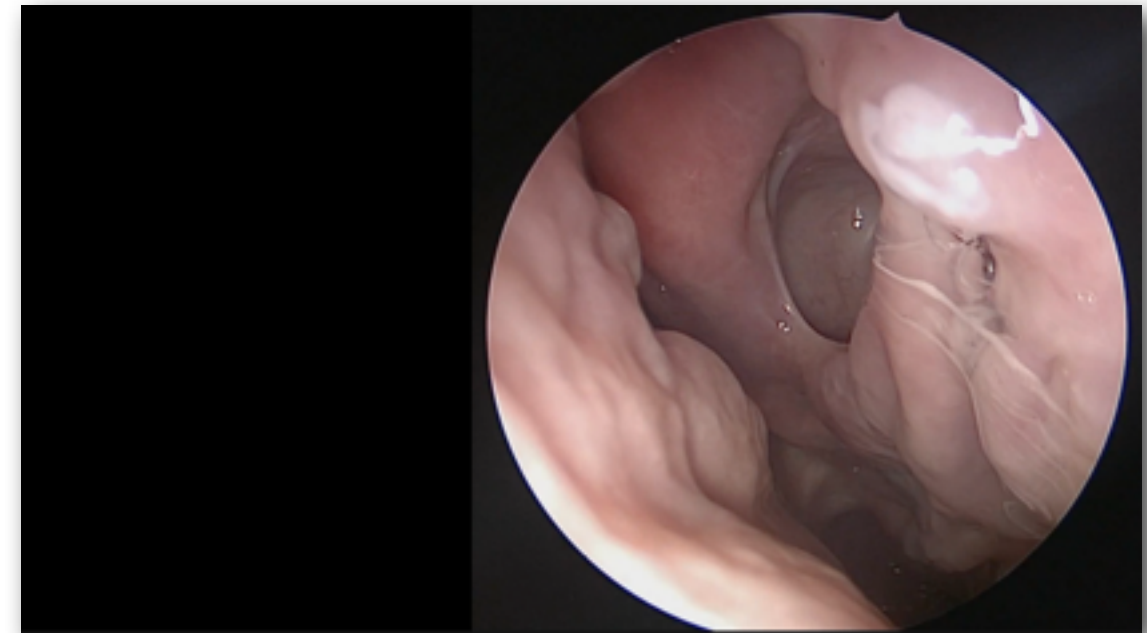
Procedure 2

Maxillary Recirculation Between Inferior and Middle Meatus

Recirculation can occur over longer distances, in this case around an intact inferior turbinate. The photos at the bottom of the page show thick mucus circulating between an inferior antrostomy and a natural maxillary ostium. An anterior fontanelle is also present.

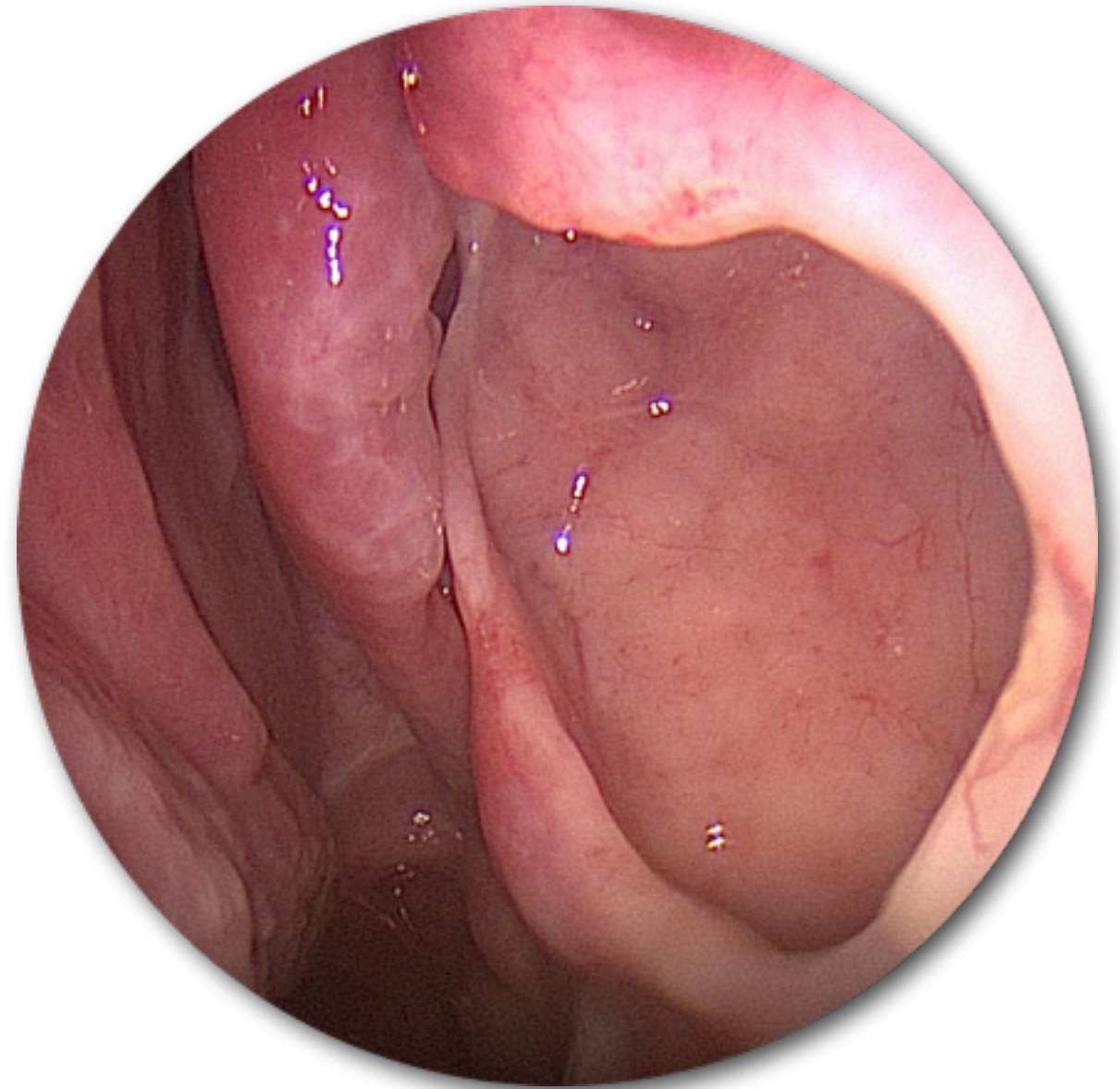
The video shows an example of office surgery performed to connect the middle meatal antrostomy with the inferior meatal antrostomy, removing the intervening inferior turbinate and lateral nasal wall to create a common ostium.

Note the hole in the inferior turbinate from previous surgery.



Follow-up

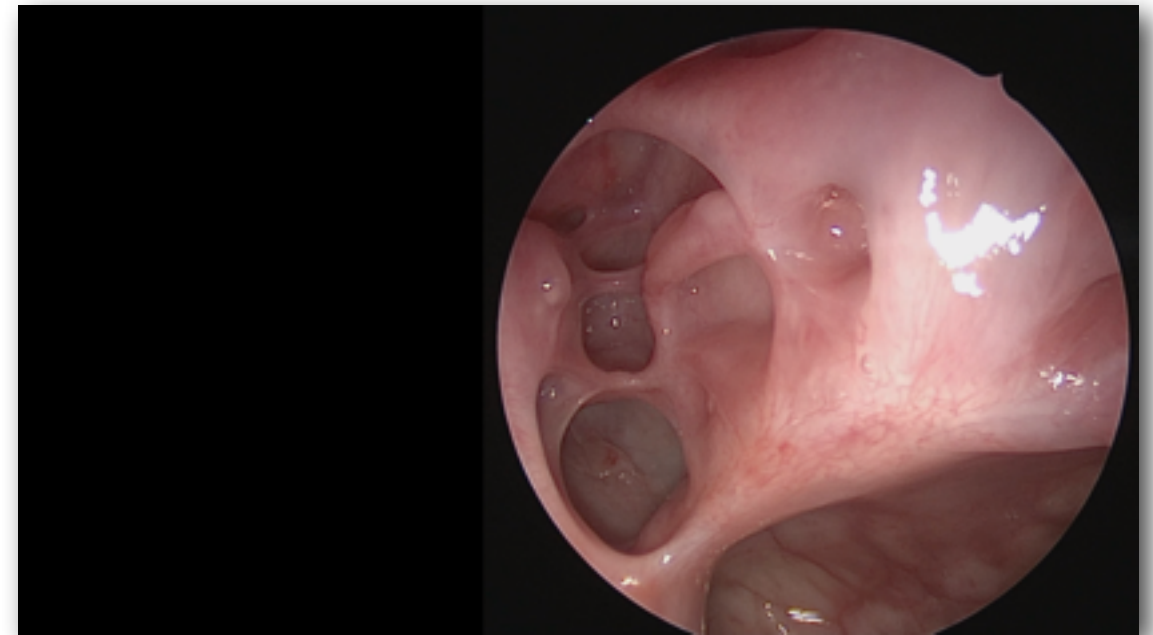
This picture demonstrates the result 10 years after office recirculation surgery.



Contraindications for Office Recirculation Surgery

This endoscopic video (70-degree scope) shows an example of a poor candidate for office recirculation surgery, due to the following factors:

- Difficult to visualize ostium
- Difficult to access the ostium with instruments
- Failed previous office procedure

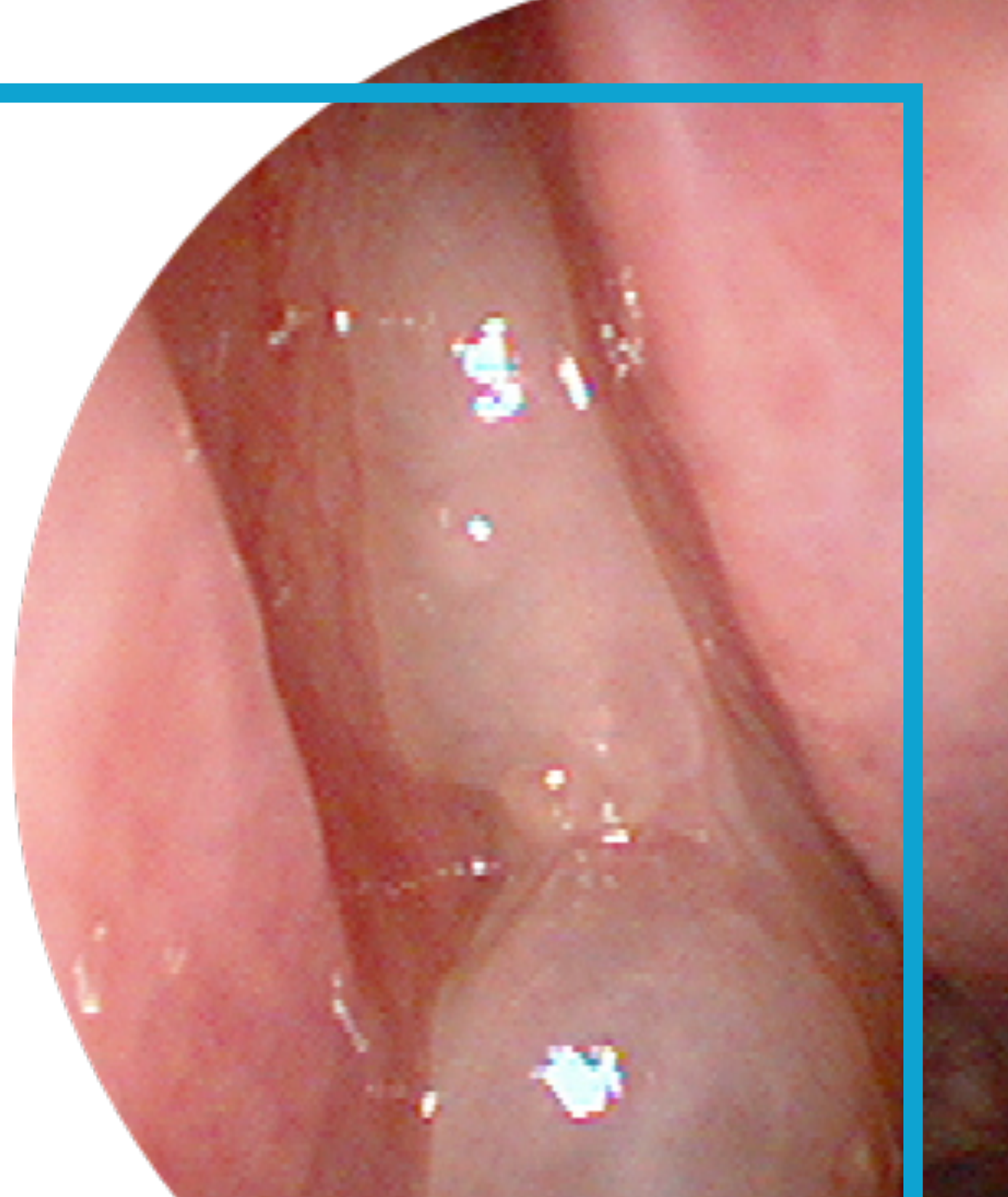


Polypectomy

Answer the question & check your answer

What are indications for office surgery for nasal polyps?

- ☐ A. Recurrent polyps after ESS
- ☐ B. Isolated central compartment atopic disease
- ☐ C. Obstructive polyps in pregnancy
- ☐ D. Sinonasal polyposis in elderly patient
- ☒ E. All of the above



Click

Check Answer

Introduction

Aside from nasal endoscopy and debridement, polypectomy is the most common interventional procedure performed by rhinologists.

Whereas a decade ago the most common indications for office polypectomies were isolated polyps and recurrence of polyps after ESS, the indications for office polypectomy have continued to expand with increased experience and comfort level with office rhinologic surgery.

Advantages¹

There is less bleeding from office polypectomy than the same procedure performed in the operating room for multiple reasons, including the lack of vasodilation from inhalational anesthesia. Also, the upright positioning of the patient decreases the engorgement of the nasal mucosa and polyps that occurs with the recumbent position.

The surgeon and staff need to make sure that the patient is not anxious, which could lead to hypertension and tachycardia, which will increase bleeding.

Patients do not typically need any nasal packing or hemostatic agents after office polypectomy.

Indications

Primary Surgery

- Solitary or limited polyps
- Middle turbinate polyps
- Isolated central compartment atopic disease (CCAD)
- Patients with significant anesthesia risk
- Patients who refuse to go to the OR
- Pregnant patients with nasal obstruction from polyps
- Patients needing symptomatic relief pending definitive surgery

Revision Surgery

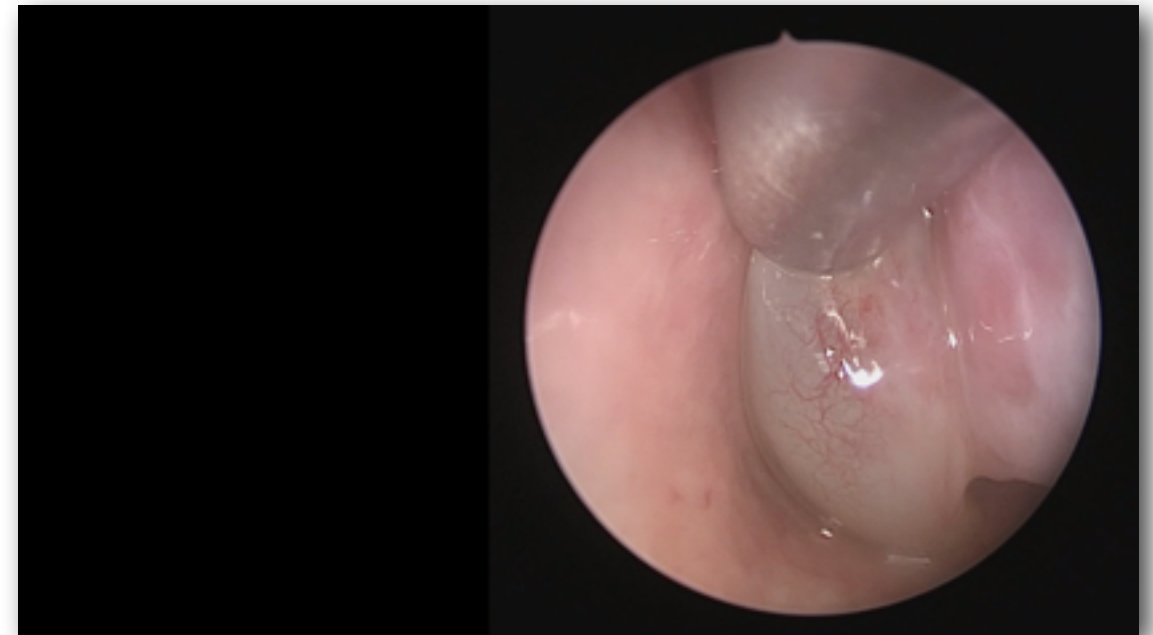
- Failed medical therapy
- Patients who refuse to go to the OR

Middle Turbinate Polyps

Isolated middle turbinate polyps or polypoid edema have been shown to be related to inhalant allergy.

Patients with isolated middle turbinate polyps have been found to represent a distinct group compared to patients with diffuse sinonasal polyposis, having significantly more inhalant allergy, less CRS, and lower Lund-MacKay scores.

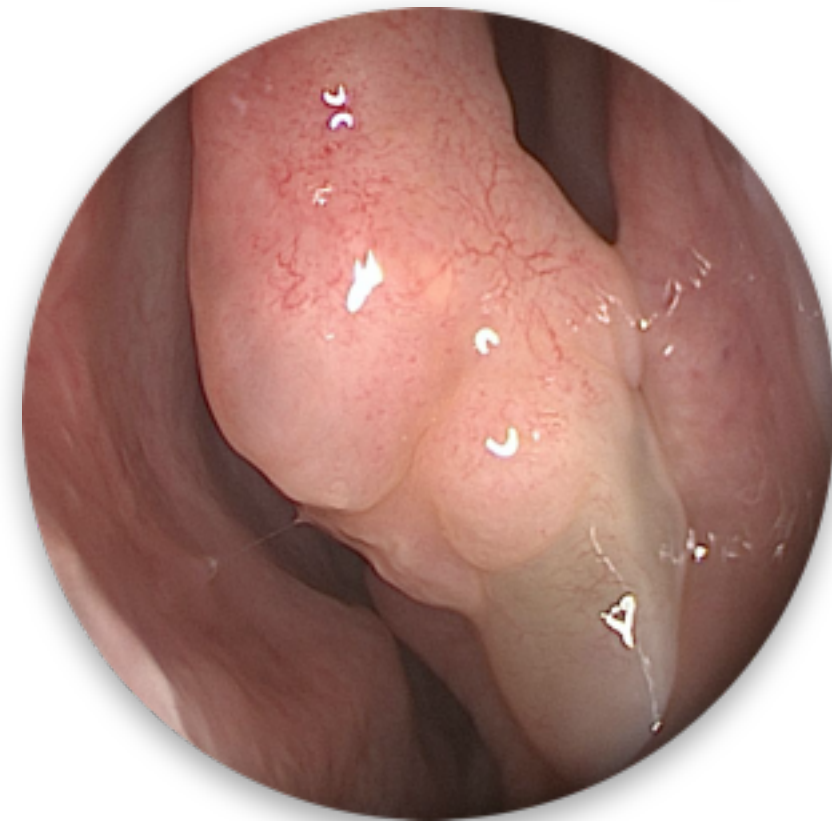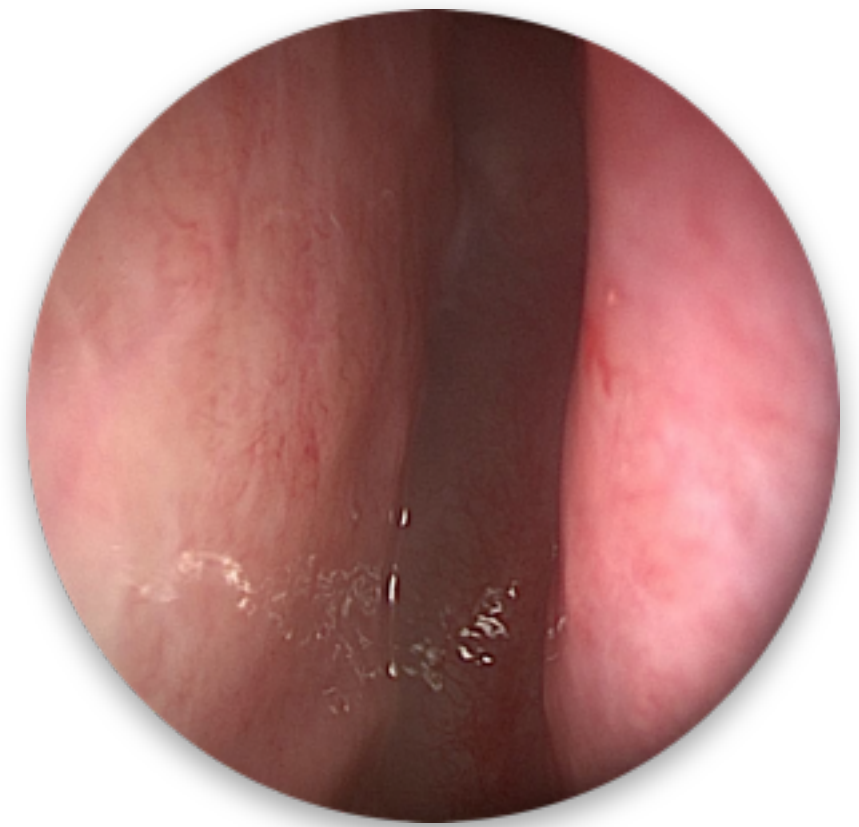
The focal disease makes them good candidates for office surgery^{5,6,7}.



Bilateral Middle Turbinate Polyps

Case

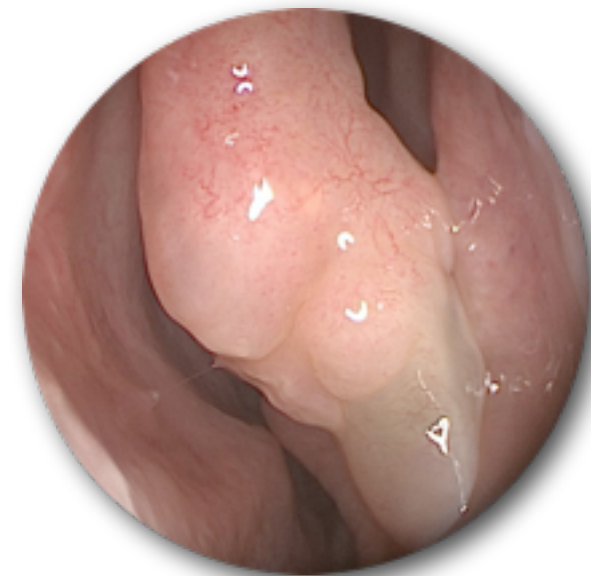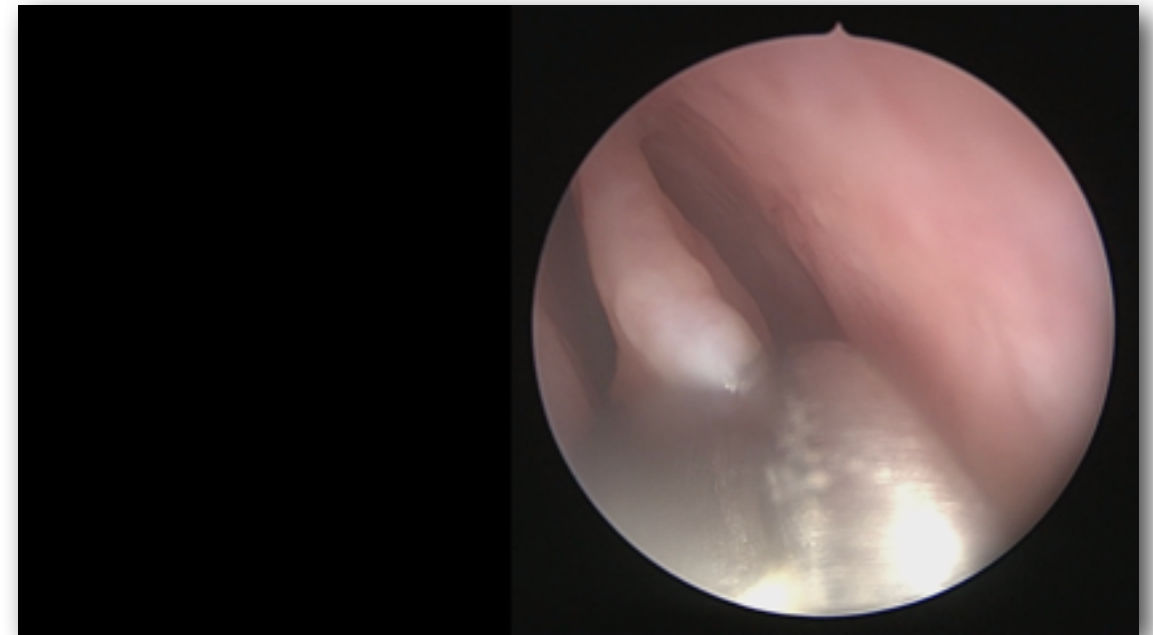
This patient has left nasal obstruction and a long history of inhalant allergies. Nasal endoscopy shows complete obstruction of the left side of the nose by a large polyp (top photo). The right side has polyps on the anteroinferior surface of the middle turbinate (bottom photo).



Isolated Middle Turbinate Polyp Resection

Procedure

Manipulation of the left-sided polyp reveals the attachment to the superior leading edge of the middle turbinate. Resection of the polyp with through-cutting forceps allows sculpting down to normal middle turbinate (video). This was also performed on the right side, as depicted on the endoscopic photos at the bottom of the page.

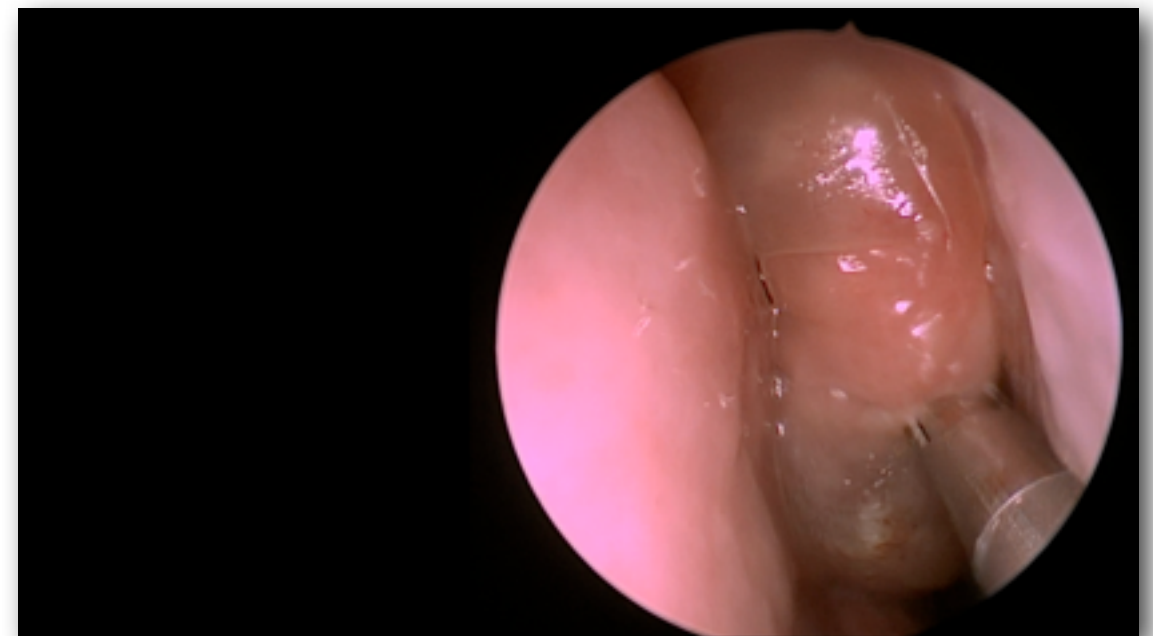
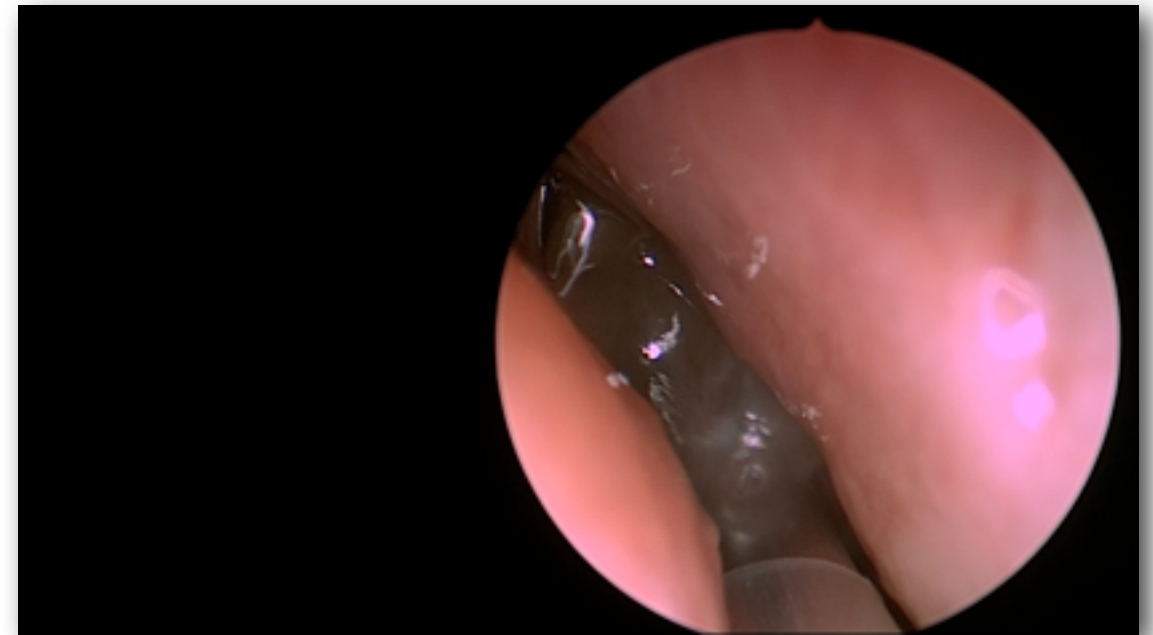


Middle Turbinate Polypoid Changes in Allergic Fungal Rhinosinusitis (AFRS)

Middle turbinate polypoid changes are common in allergic fungal rhinosinusitis (AFRS), since this is an IgE-mediated condition. Even when the sinus disease has been controlled with surgery, the middle turbinates can become polypoid and lead to nasal obstruction. This is likely a protective mechanism to filter inhaled allergens from reaching the sinuses.

These endoscopic photos are from a 28-year-old female at the end of her first trimester of pregnancy, with recurrent bilateral nasal congestion. She had undergone ESS for AFRS 10 years previously. There is obvious severe polypoid degeneration of the middle turbinates.

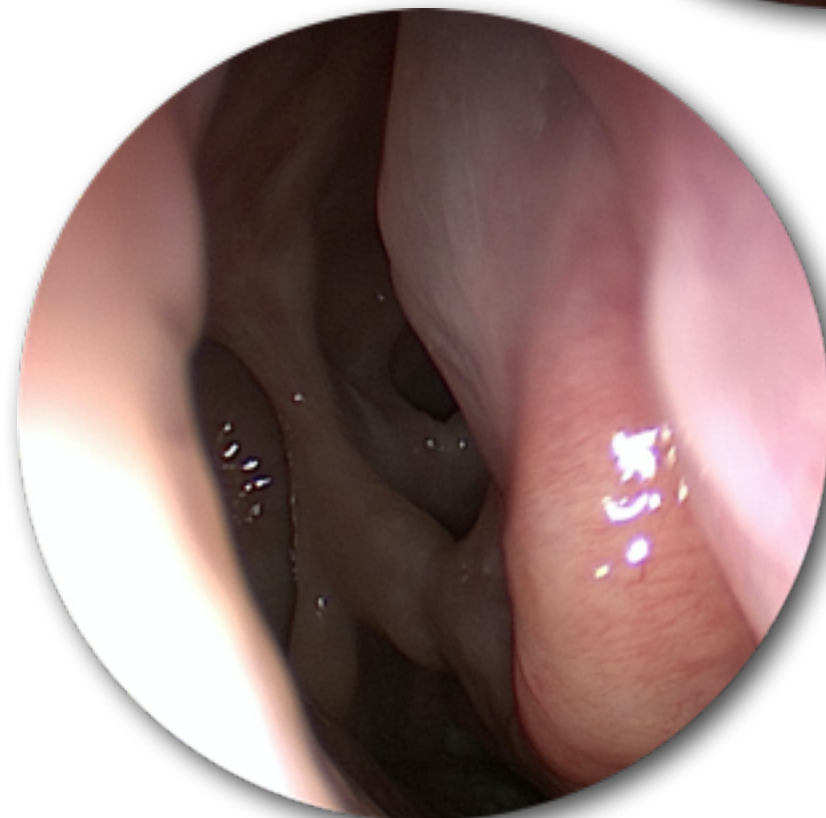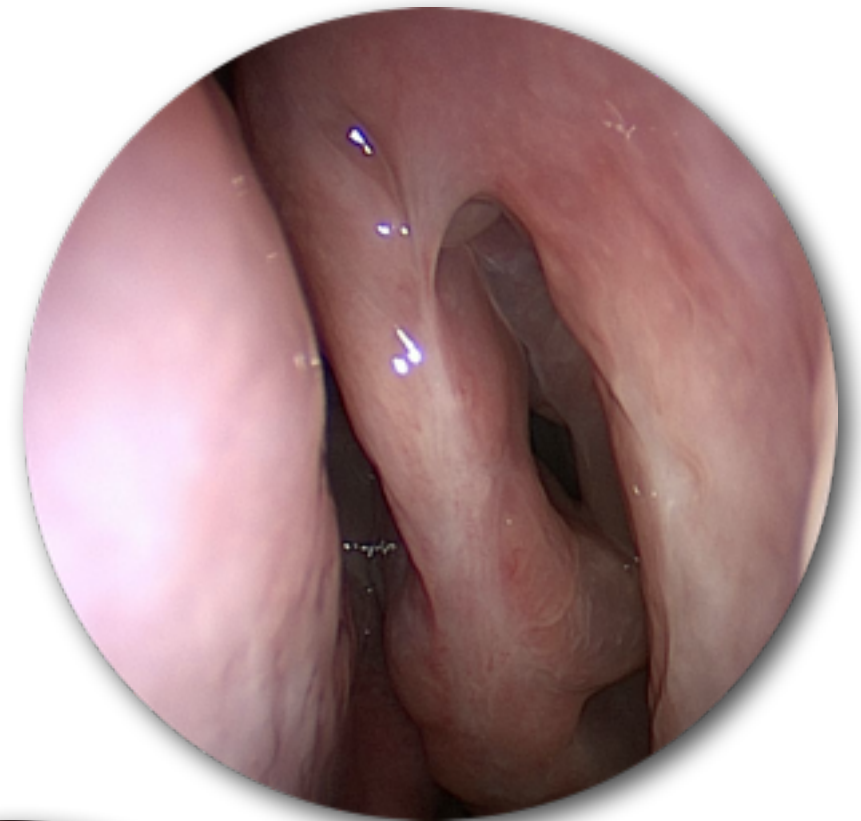The patient underwent bilateral microdebrider sculpting of the middle turbinates.



Results of Middle Turbinate Polyp Removal

One-month after office sculpting of the polypoid middle turbinates, the nasal obstruction is resolved.

The patient has been maintained on topical steroid irrigations. Note that the sinuses are clear without mucosal disease, reflecting the protective function of the middle turbinates.

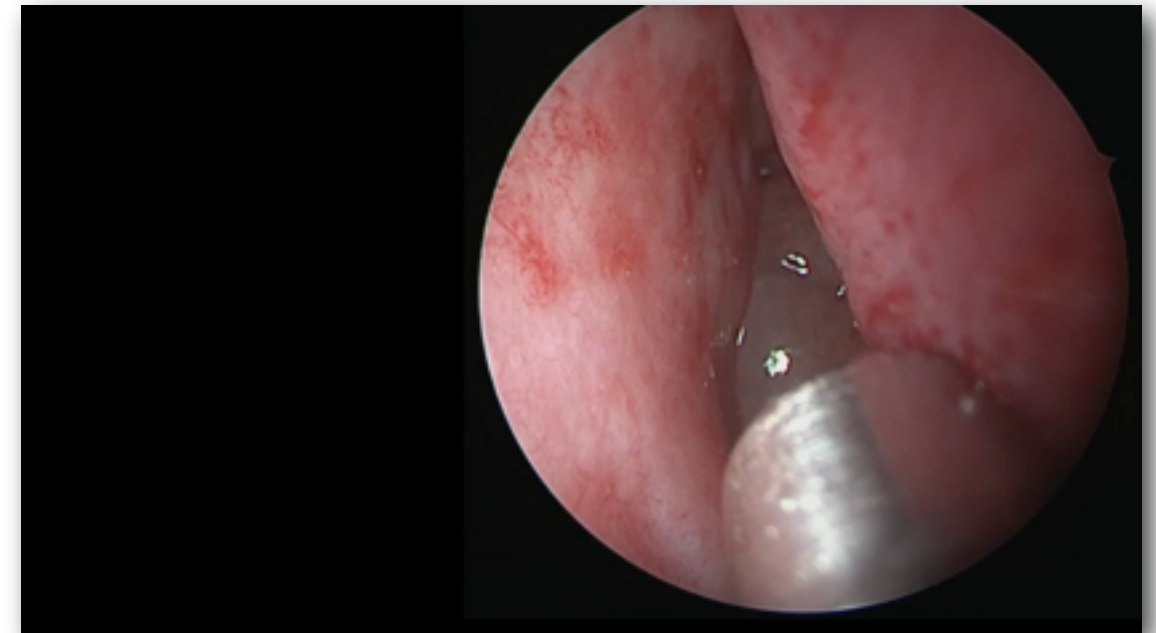
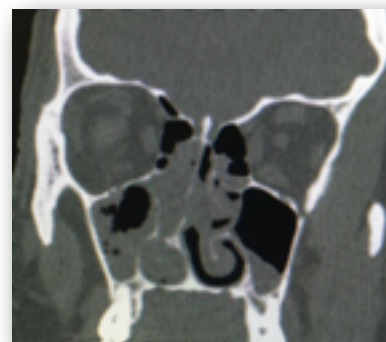

Specific Pathology

Central Compartment Atopic Disease (CCAD)

Definition

CCAD is a nasal inflammatory condition associated with inhalant allergy, that manifests as polypoid changes involving the middle turbinate, superior turbinate, and/or posterosuperior nasal septum. As this is a nasal inflammatory condition, the sinuses are not involved early in the disease process. As the central compartment polyps progress, the sinuses can be secondarily obstructed by polypoid changes of the middle turbinate, or by lateralization of the middle turbinate due to septal polyps. CT scan of the sinuses shows central sinus involvement with lateral and superior clearing with early sinus involvement, with progression laterally with advanced stages. This CT pattern is distinct from inflammatory sinus disease.



DelGaudio JM, Loftus PA, Hamizan A, Harvey RJ, Wise SK. Central Compartment Atopic Disease. [Amer J Rhinol Allergy. 2017;31\(4\):228-234.](#)

Hamizan AH, Loftus PA, Alvarado R, Ho J, Sansoni E, DelGaudio JM, Harvey RJ. Allergic phenotype of chronic rhinosinusitis based on radiologic pattern of disease. [Laryngoscope 2018; 128 \(9\):2015-2021.](#)



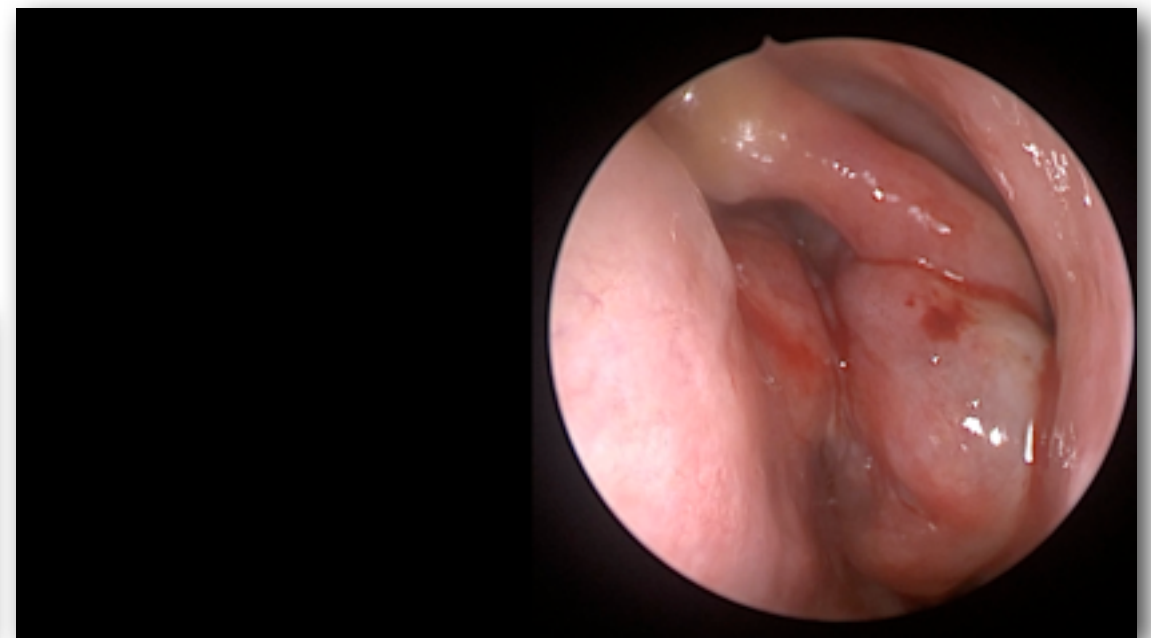
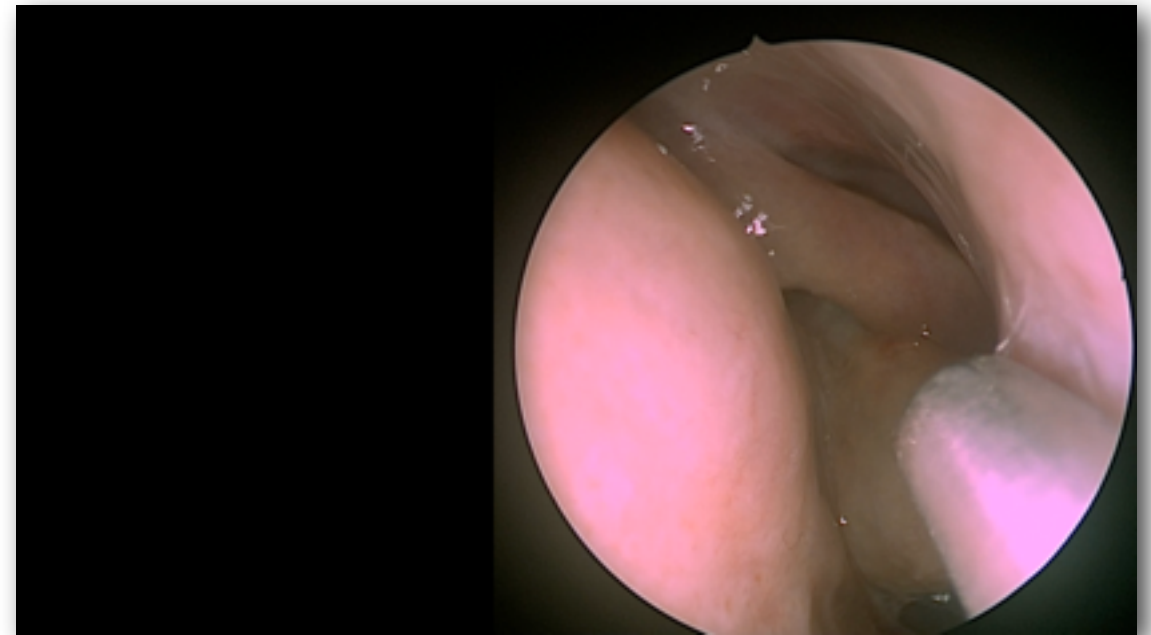
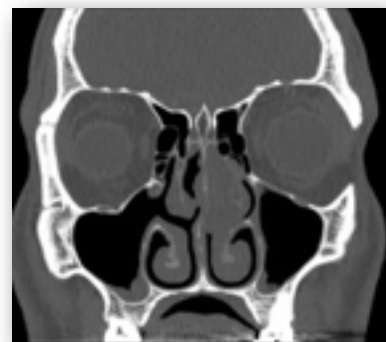
Indication

CCAD patients with little or no sinus involvement are ideal candidates for office surgery, as the pathology is located in the central portion of the nose.

Case

This patient had long-standing allergies and left-sided nasal obstruction. CT and endoscopy show central compartment polyps involving the left nasal septum and middle turbinate.

Office surgery was performed with removal of the central compartment polyps. Notice that the polyps originate from the posterosuperior nasal septum and the middle turbinate, consistent with CCAD.

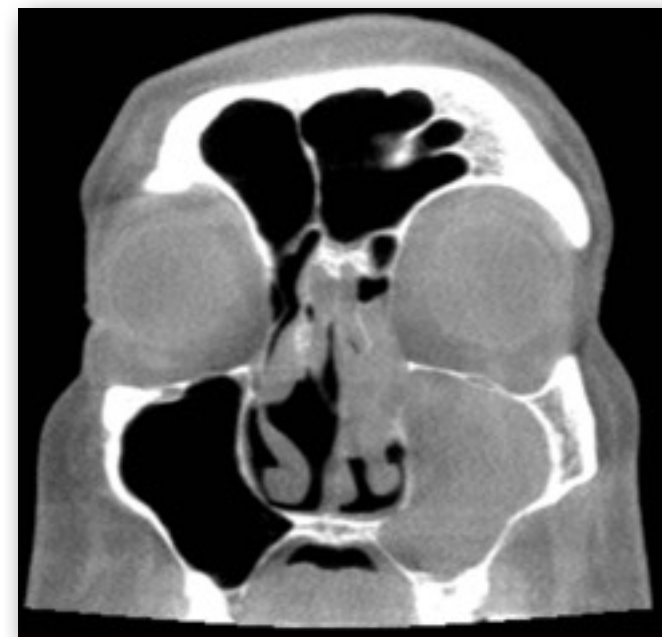
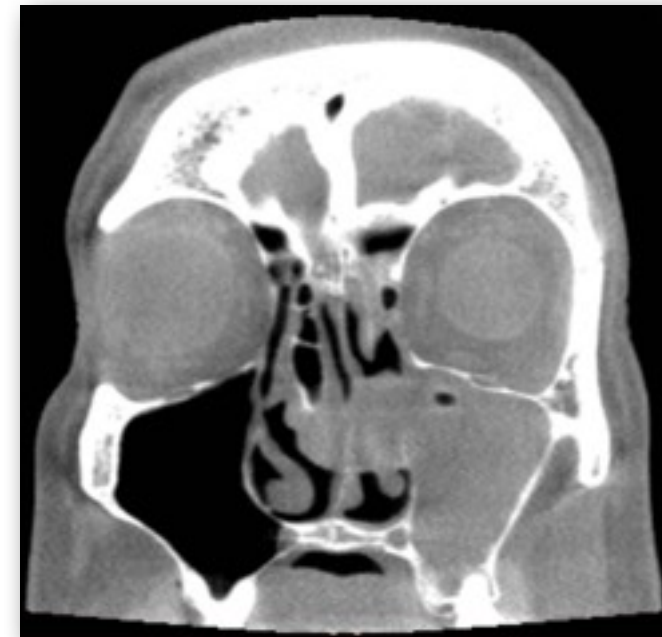

Case

With advanced CCAD, the sinuses can become obstructed by lateralization or polypoid changes of the middle turbinates.

This is the case in this 67-year-old male with a long history of seasonal allergic rhinitis and previous sinus surgery 20 years ago. He complains of left nasal obstruction and a foul odor in his nose.

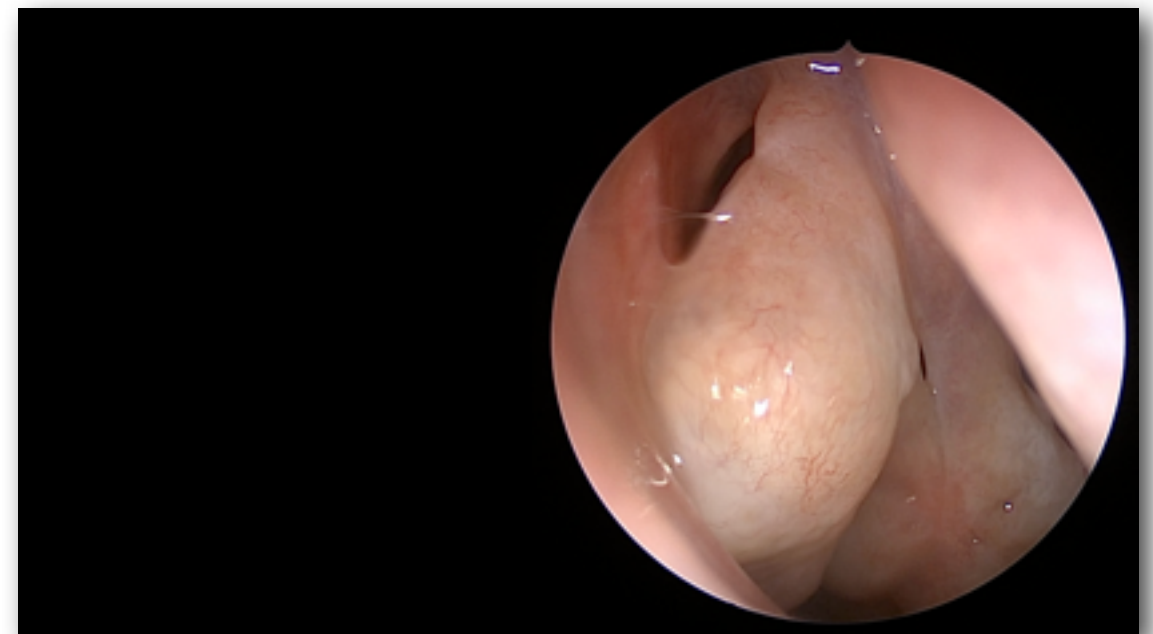
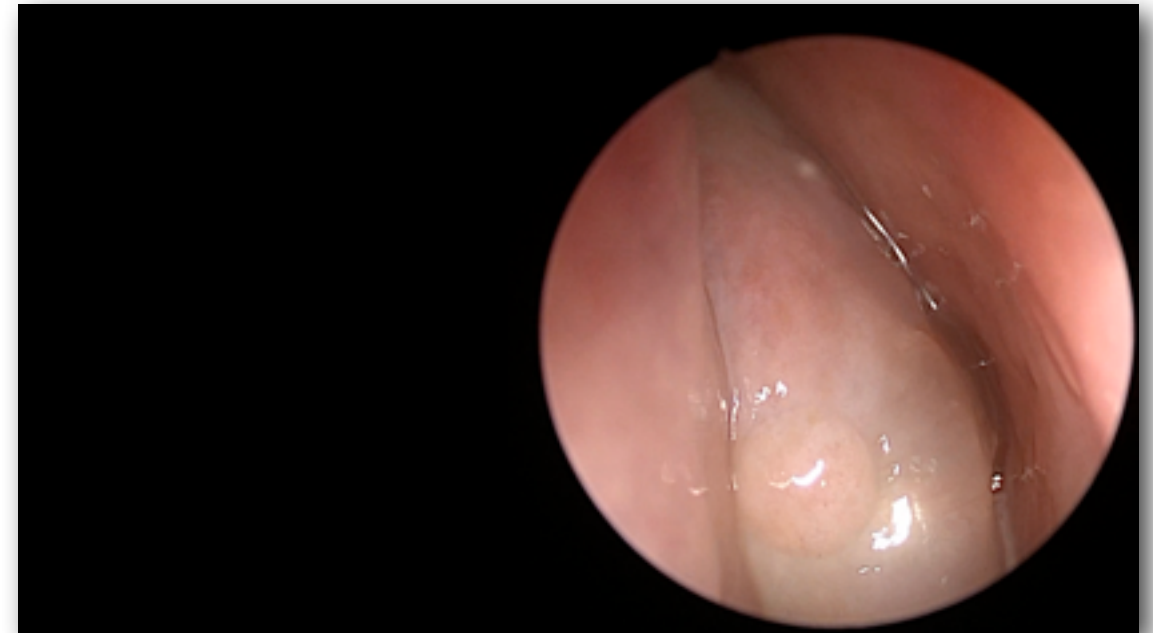CT scan demonstrates left nasal cavity soft tissue and an opacified left maxillary sinus.



Procedure

Central Compartment Atopic Disease (CCAD) with secondary obstructive maxillary sinusitis

Nasal endoscopy shows bilateral polypoid middle turbinates. The left middle turbinate is plugging the maxillary sinus (top photo), and the right middle turbinate is polypoid and has a concha bullosa (bottom photo).

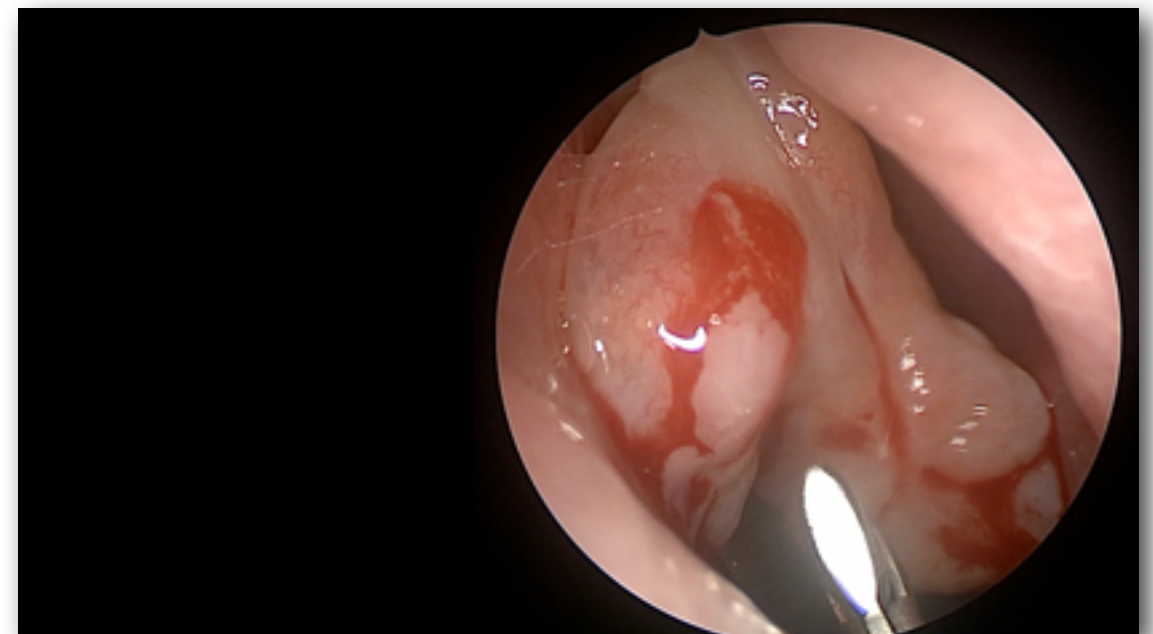
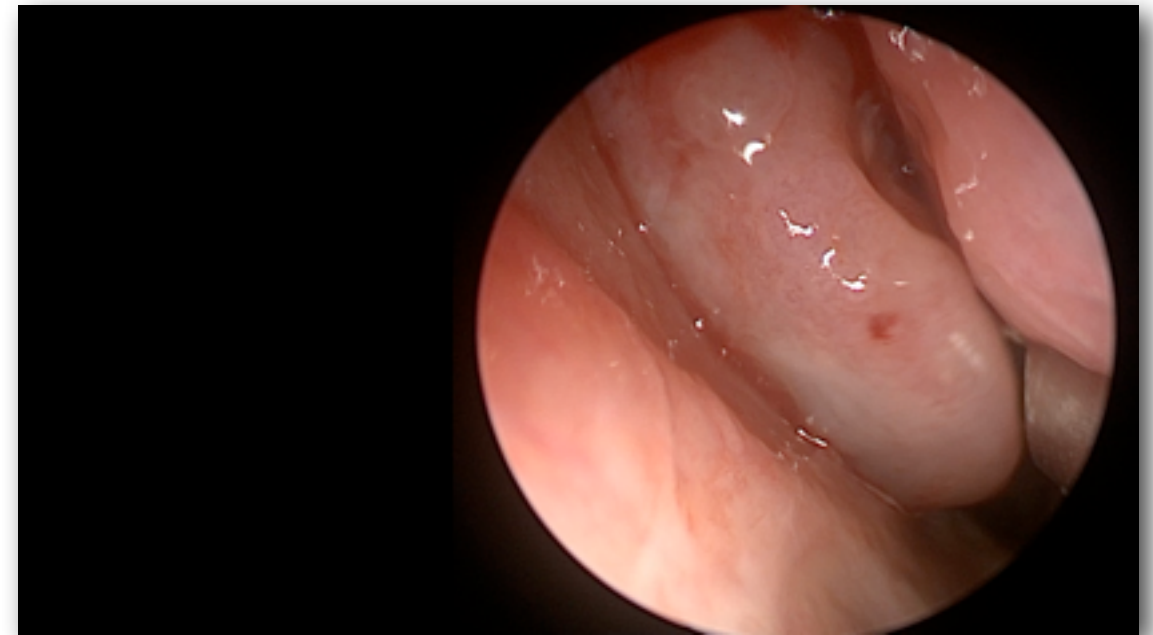


Procedure (top video)

Left middle turbinate polyp resection and maxillary antrostomy for CCAD with maxillary obstruction.

Procedure (bottom video)

Right concha bullosa resection.



Antrochoanal Polyp

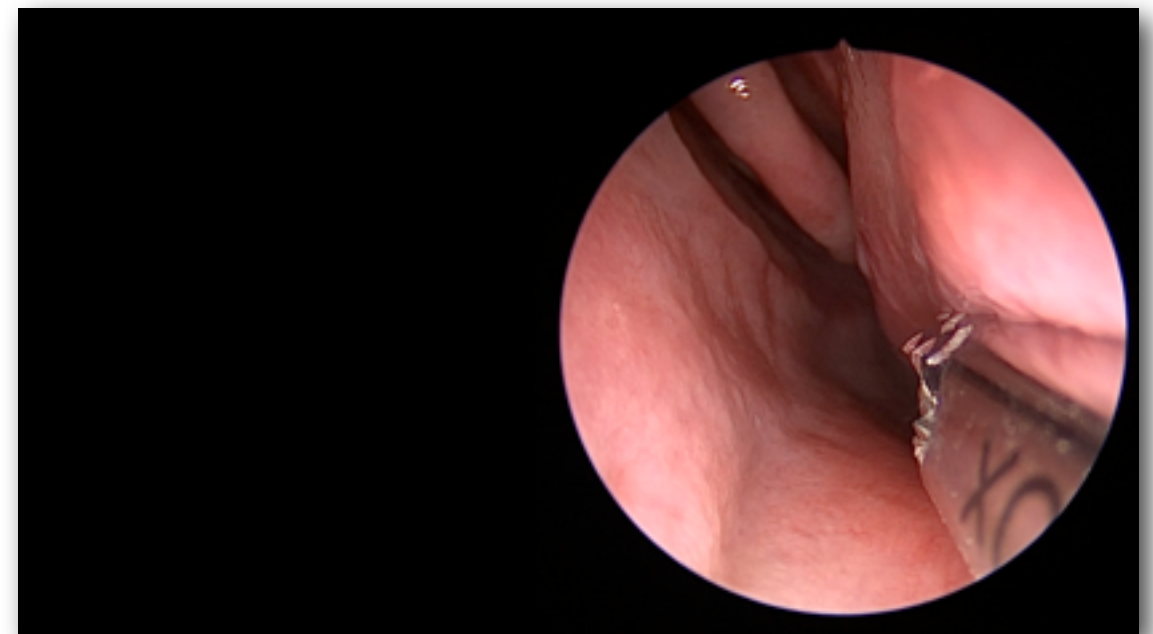
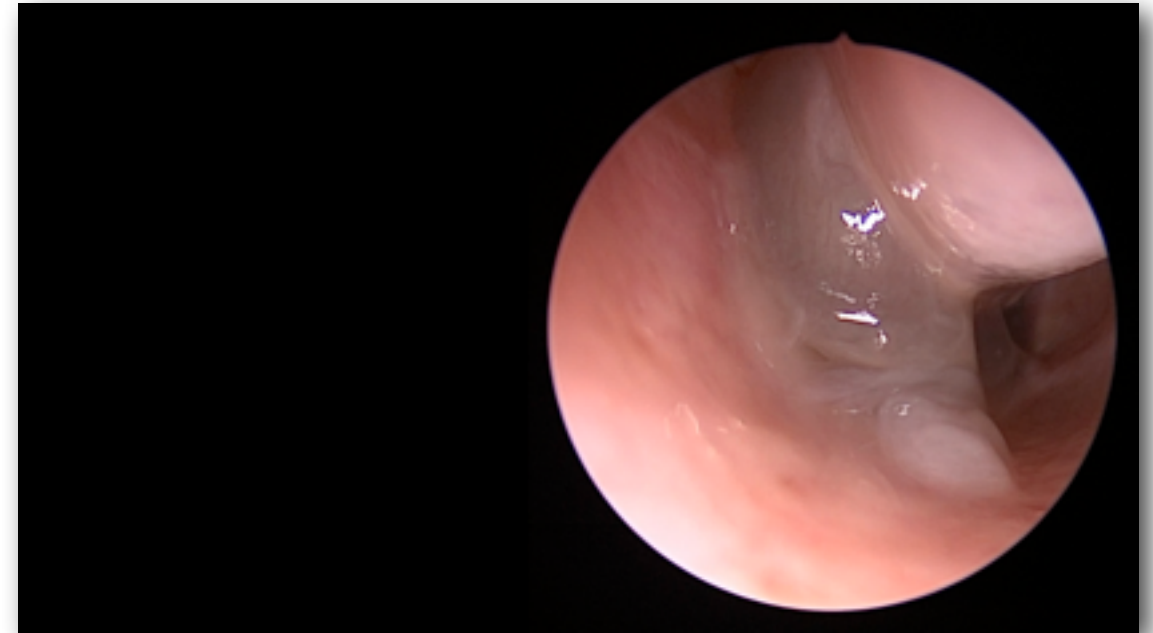
Case

Polyps occurring during pregnancy can cause significant nasal obstruction. This is a 35- year-old woman who is 15 weeks pregnant, with near complete left nasal obstruction.

Nasal endoscopy shows what appears to be an antrochoanal polyp.

The patient requests a procedure to relieve her nasal obstruction. Therefore, an office polypectomy was performed with a microdebrider, resecting the polyp to where it exited from the maxillary sinus.

While this wasn't a curative procedure because the maxillary sinus portion was not addressed, it did provide significant and prolonged relief of her nasal obstruction.



Chronic Rhinosinusitis with Nasal Polyps, Primary Polypectomy

Case

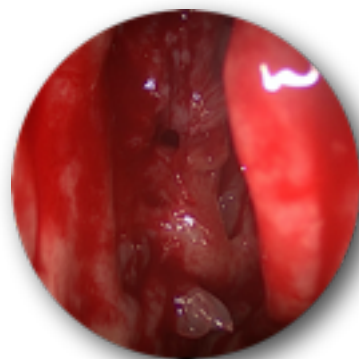
Elderly patients are good candidates for office surgery.

An 80-year-old male had a long history of unilateral nasal obstruction. He was noted to have polyps on endoscopy for several years. The patient had no previous surgery and didn't want to have surgery in the operating room.

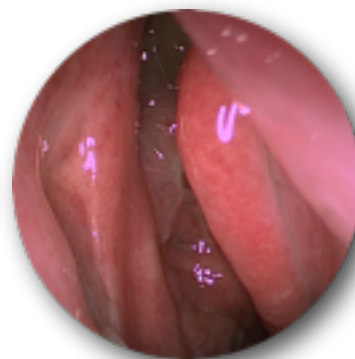
CT of the sinuses shows right-sided middle meatal polyps with minimal maxillary and ethmoid sinus disease.

The patient underwent office polypectomy with a microdebrider under topical and local anesthetic to clear the middle meatus of polyps. The patient had a great improvement of his symptom of obstruction and was maintained on topical steroid rinses.

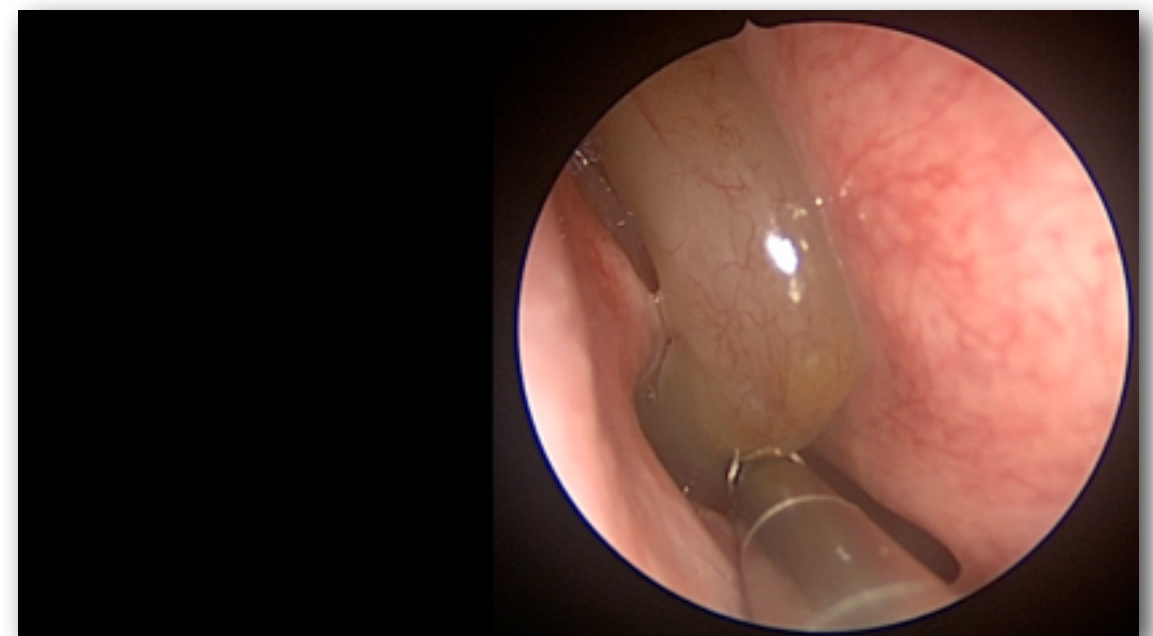
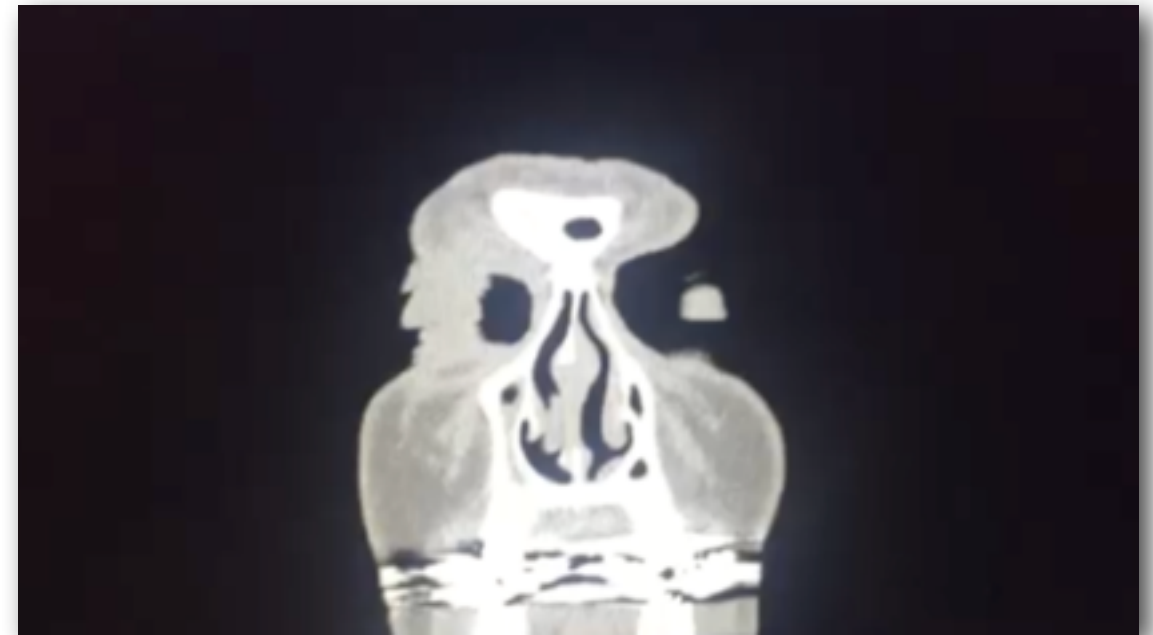Follow up



immediate postop



1-month postop

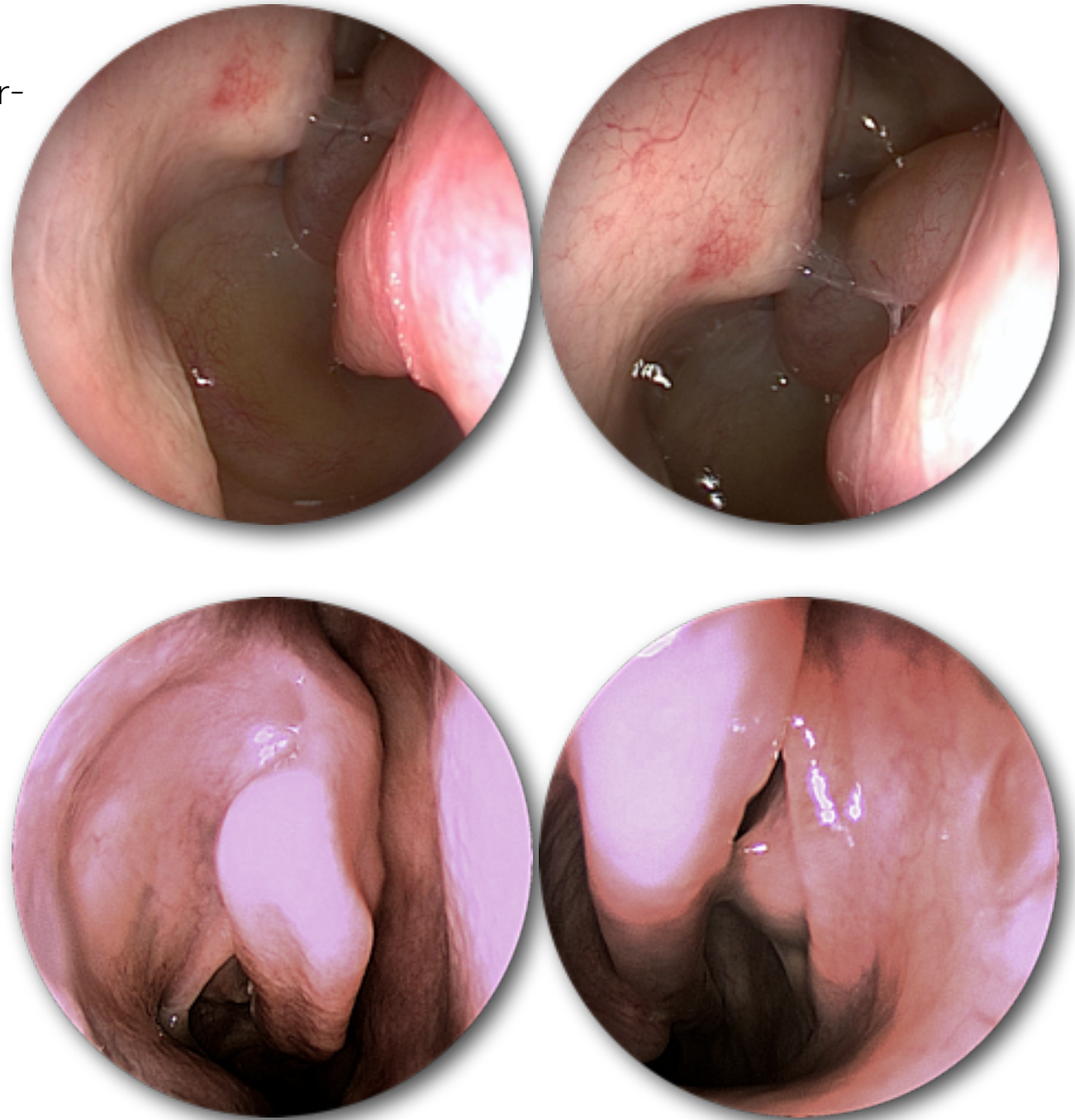


Case 2

This is a similar case with bilateral polyps.

An 80-year-old retired physician had several years of near-complete nasal obstruction. He preferred not to have surgery in the operating room.

He underwent office polypectomy with a microdebrider with excellent results, which were maintained on topical steroid rinses.



Recurrent Nasal Polyps

The mainstay of treatment for CRSwNP after ESS is high-volume topical steroid irrigations. When medical treatment fails or is not tolerated, office-based polypectomy can serve to reduce the inflammatory burden.

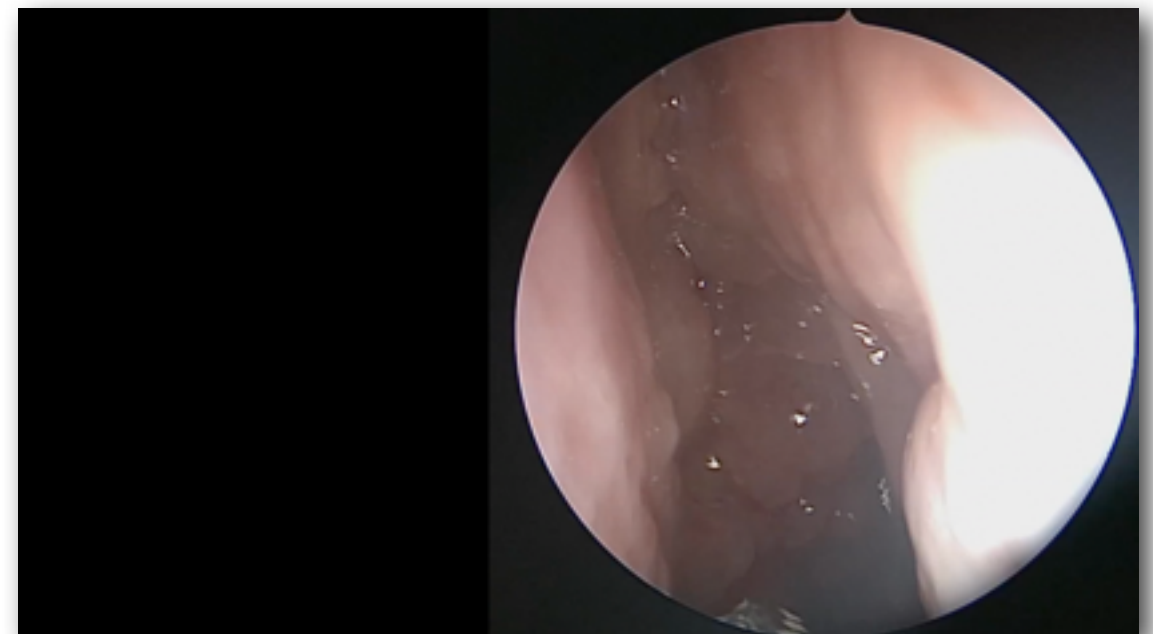
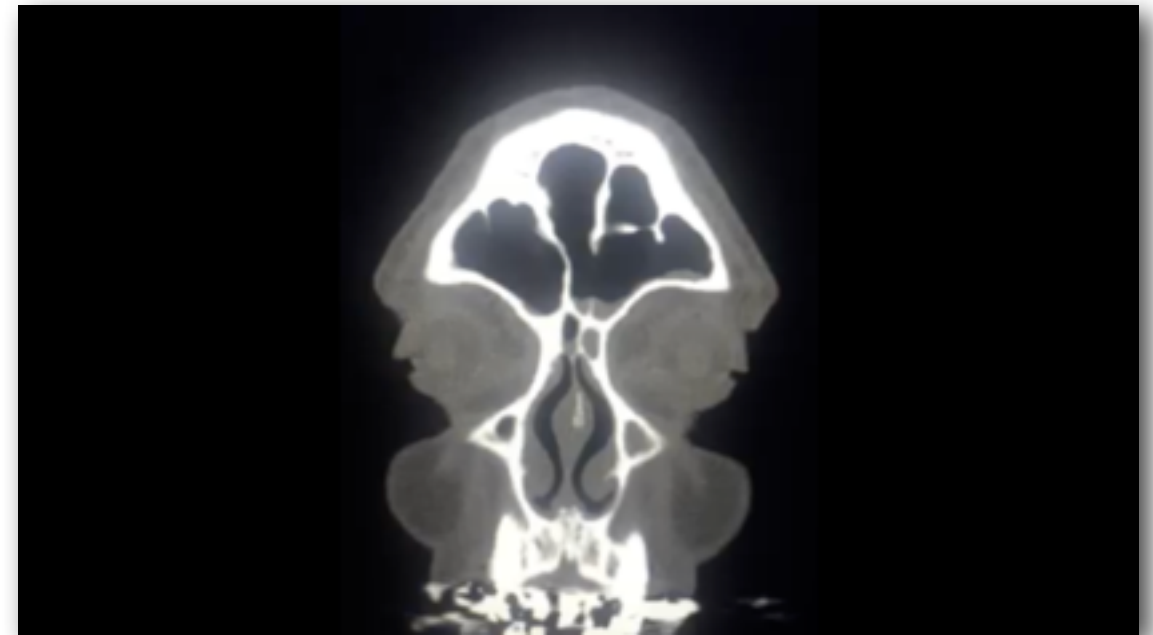This may reset the patient's baseline and allow medical therapy to be effective.

Case

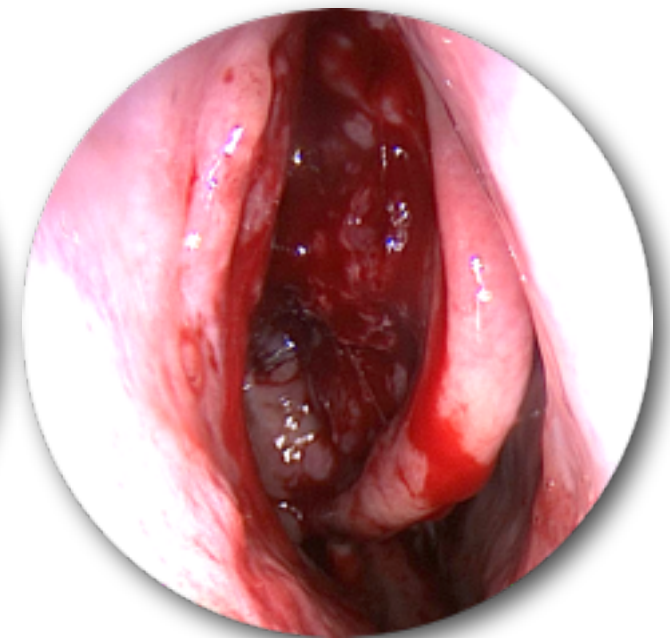
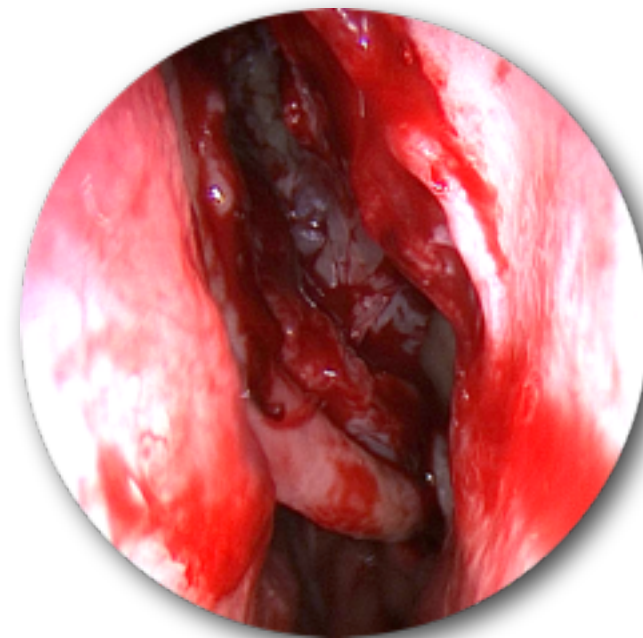
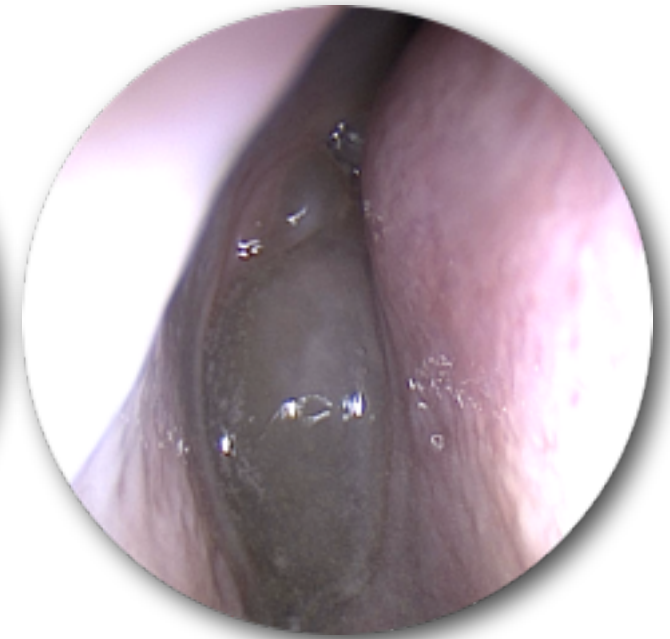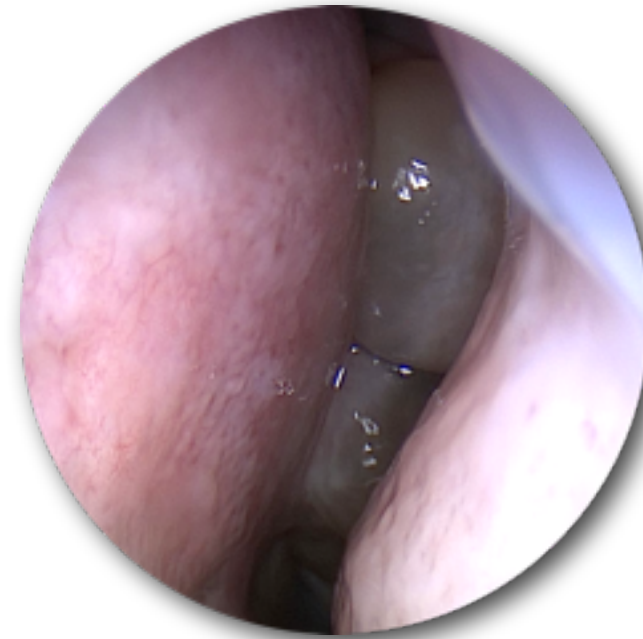The patient in this video had previous ESS for polyps but recurred despite adequate postoperative medical therapy.

Revision total ethmoidectomy and frontal sinusotomy was performed with a microdebrider to remove polyps, decrease the inflammatory burden, and reopen the sinuses.

The patient was then continued on topical steroid rinses.



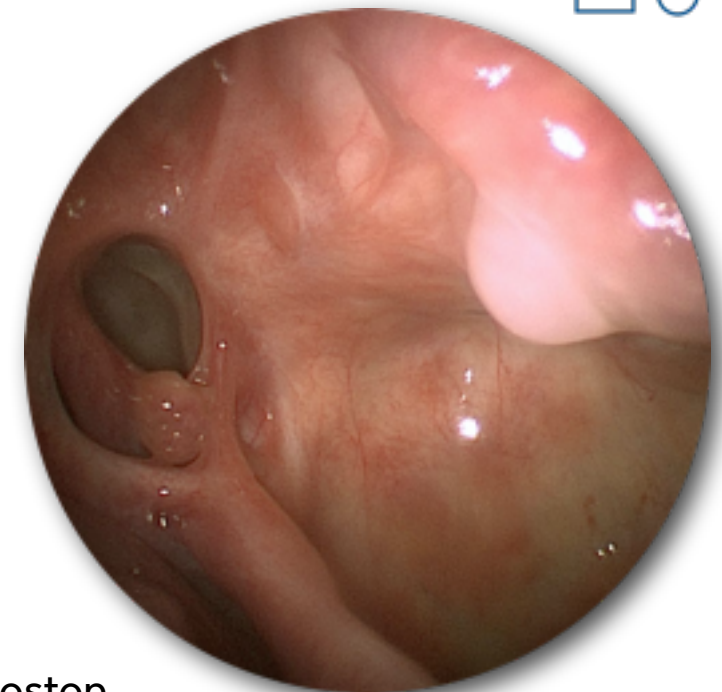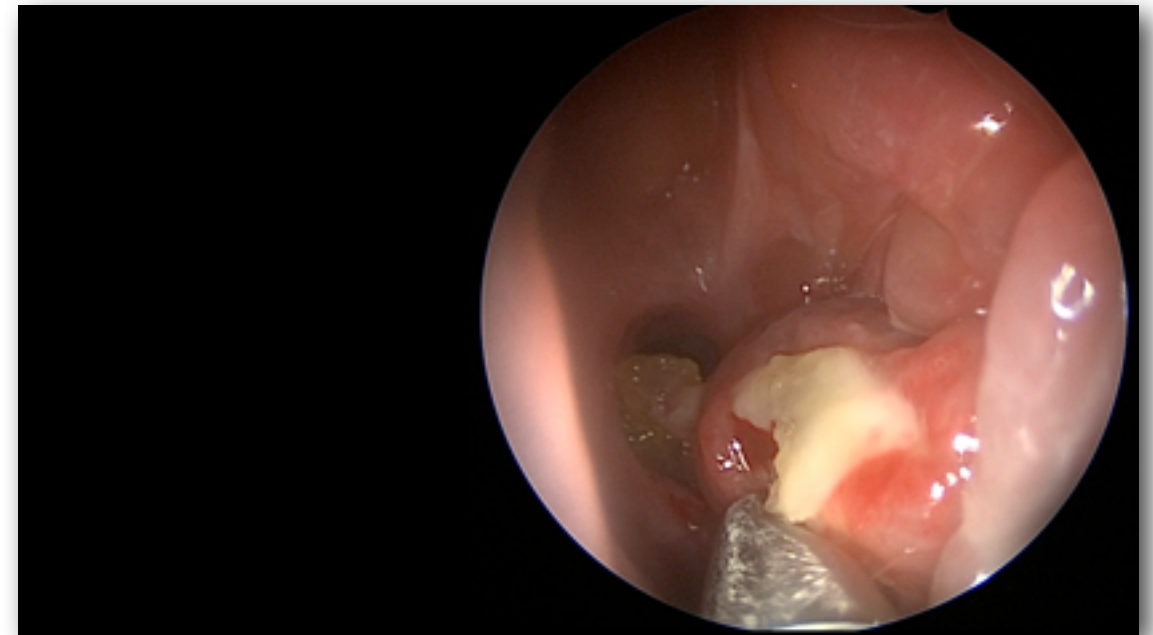
Office Polypectomy Results



Revision Maxillary Antrostomy for Recurrent Polyps in AFRS

This patient underwent ESS for AFRS with good results but had recurrent polyps in the left maxillary sinus that were not responsive to medical therapy.

Rather than take the patient to the operating room, an office maxillary antrostomy was performed to remove as much of the polyps as possible. Even though the anterior portion of the maxillary sinus could not be accessed, the patient had an excellent outcome, as the polyp debulking was enough to allow the steroid irrigations to reach the maxillary sinus and control the remaining disease.



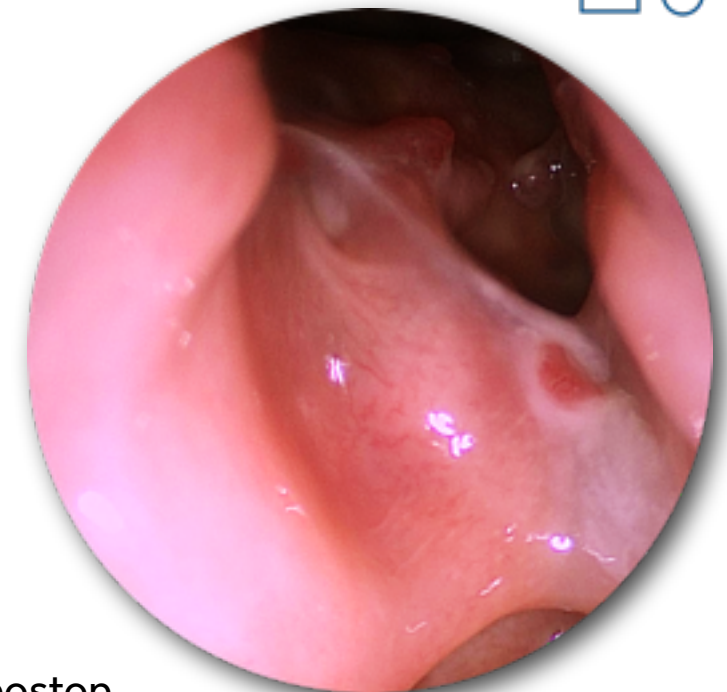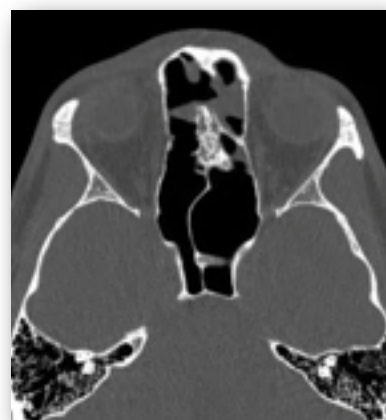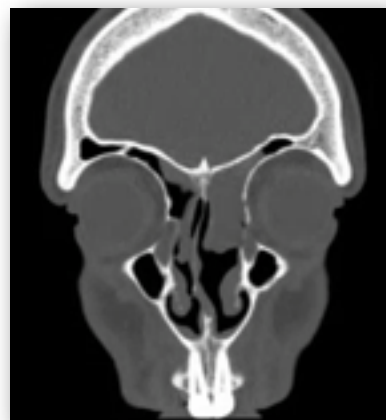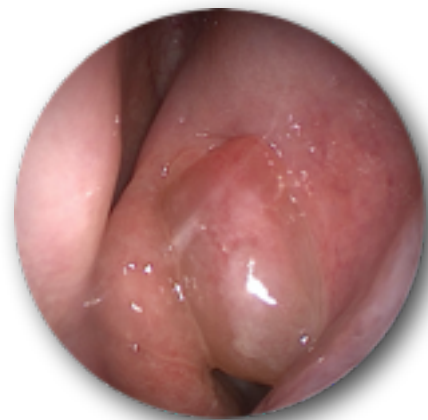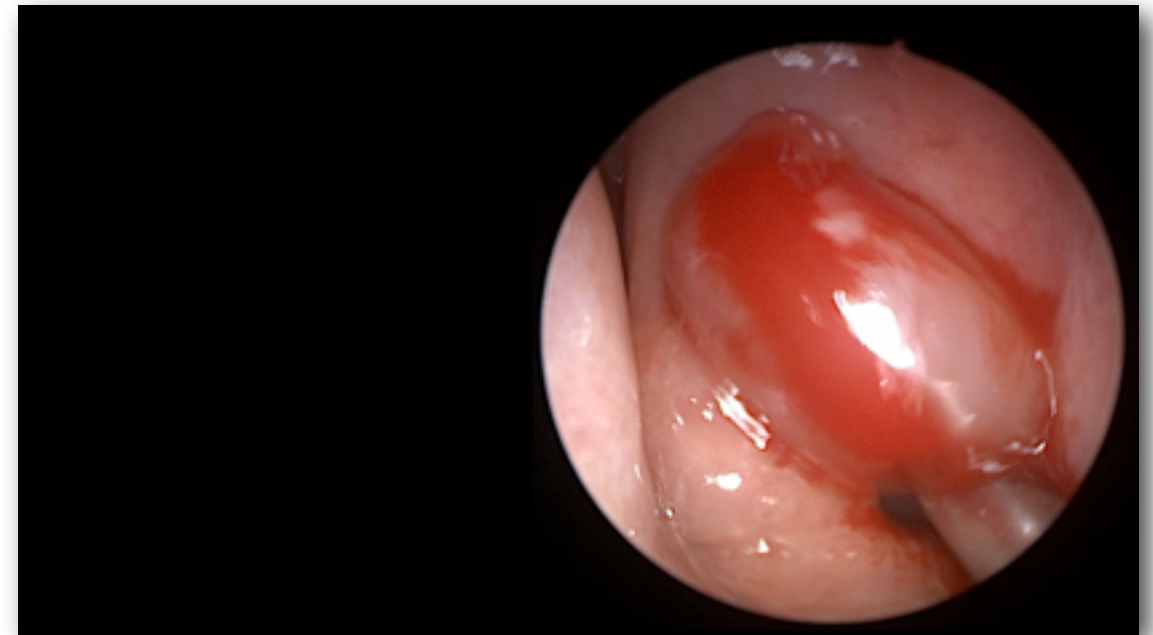1 months postop

Recurrent Frontal Recess/Sinus Polyps in AFRS

Similar to the last case, this 25-year-old male had undergone previous surgeries for AFRS.

He was on high-volume topical steroid rinses and other medical therapies without resolution. CT scan and endoscopy show isolated anterior ethmoid and frontal recess/sinus disease.

The patient underwent office frontal sinusotomy with excellent results, maintained with topical steroid rinses.



1 months postop

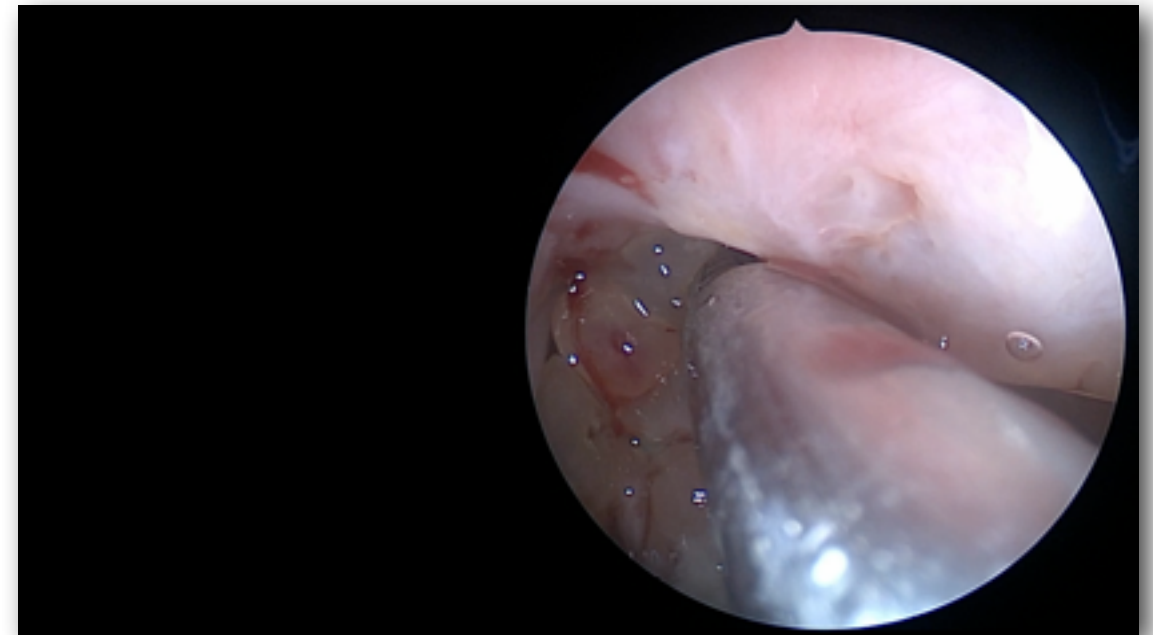
Relative Contraindications for Office-Based Polypectomy

Patients with significant retained bony septations within the ethmoid sinuses are much more difficult to treat in the office setting, especially if there is osteitis or neo-osteogenesis.

Patients with NonSteroidal Drug -Exacerbated Respiratory Disease (NERD) are more difficult and have poorer results after office polypectomy due to the more fibrous nature of the polyps.

This is a 67-year-old male with a history of NERD. He had undergone multiple ESS, including a Draf 3 procedure one-year earlier. He had recurrent polyps in the frontal recess and frontal sinuses despite adequate medical therapy, including aspirin desensitization and topical steroid rinses.

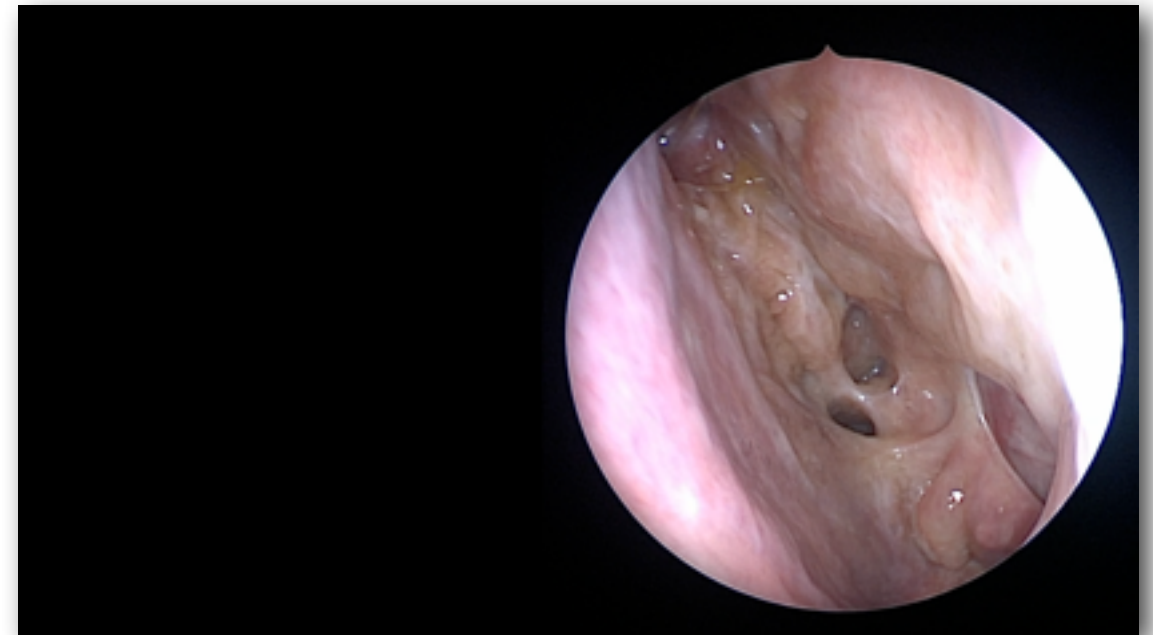
Office frontal sinusotomy to remove the polyps was performed with a microdebrider, with significant improvement but not complete removal.



Recurrent Frontal Recess/Sinus Polyps

This video shows the results 3 months after office polypectomy for NERD.

Although there is improvement compared to the preoperative status, there has been some progression of the polyps in the frontal recess and frontal sinus. This is not unusual for NERD patients with multiply recurrent polyps.



Conclusions

Office nasal polypectomy is the most common procedure performed by rhinologists. The indications for office polypectomy are continuing to expand. Office polyp removal does not preclude the need for medical therapy, but rather resets the inflammatory baseline to allow medical treatment to be more effective.

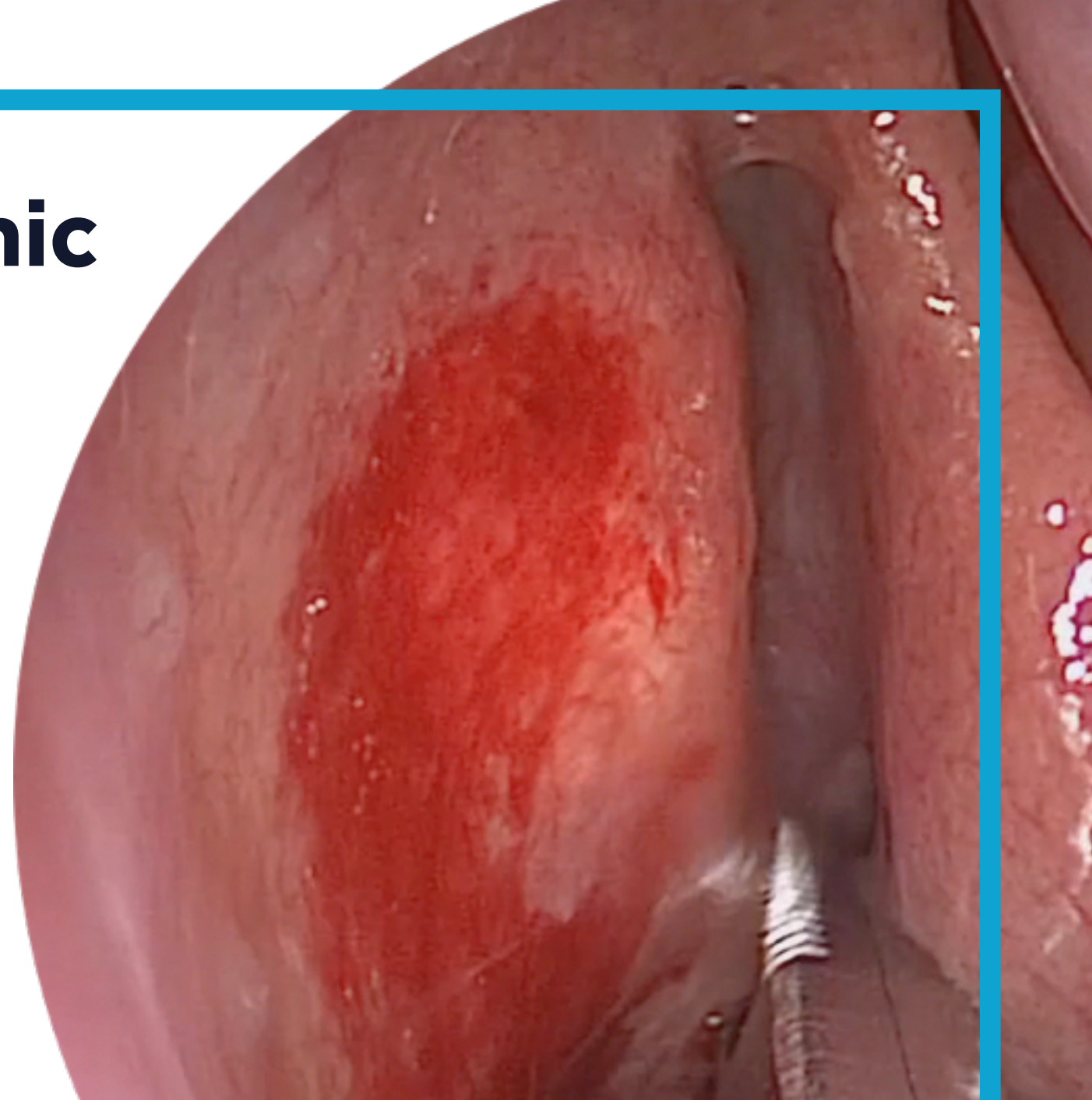
Office polypectomy can be an important part of long-term care of CRSwNP patients. The physician and patient should have realistic expectations for the results of office polypectomy.

Fungus Ball & Chronic Rhinosinusitis

Answer the question & check your answer

What type of primary sinus surgery can be performed in the office setting?

- ☐ A. Maxillary antrostomy
- ☐ B. Ethmoidectomy
- ☐ C. Sphenoidotomy
- ☐ D. Frontal sinusotomy
- ☒ E. All of the above



Click

Check Answer

Medtronic
Further, Together

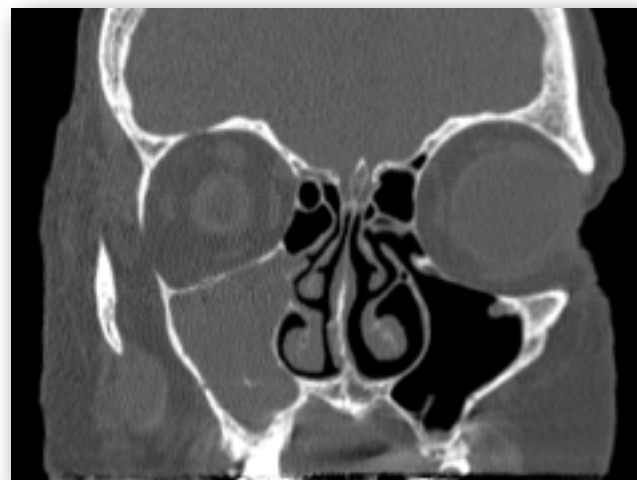
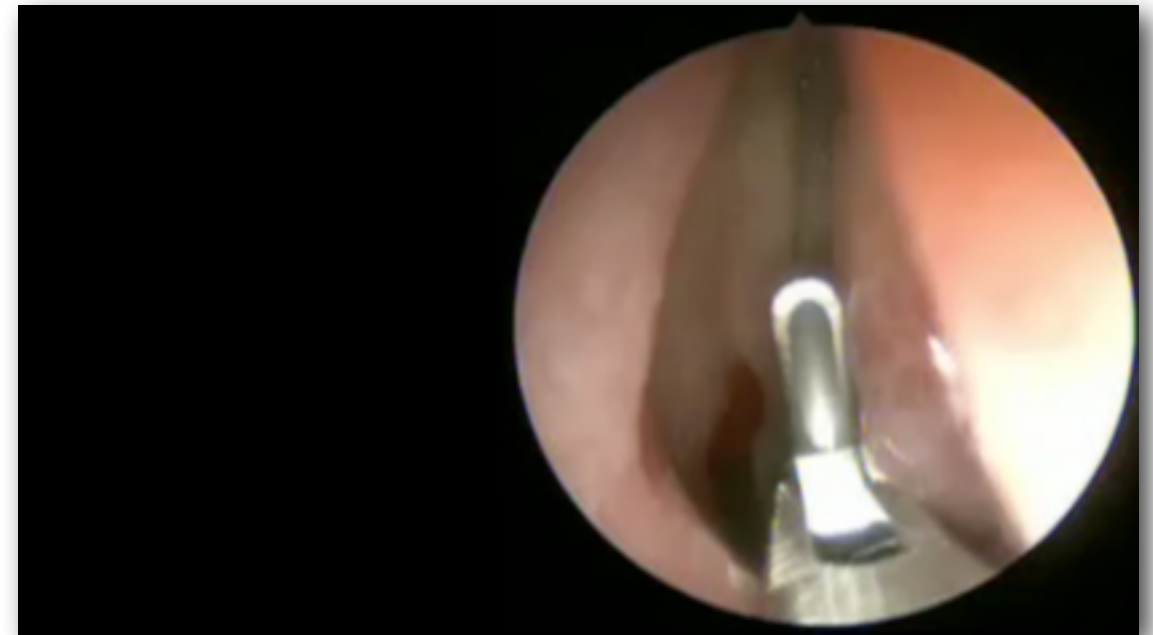Primary Maxillary Antrostomy for Fungus Ball

Fungus balls typically involve a single sinus, with the maxillary sinus being the most common, followed by the sphenoid sinus.

Areas of hyperdensity, as seen in the bottom of the maxillary sinus on this CT scan, are common in fungus balls.

Treatment involves widely opening the sinus and clearing the contents, as seen in this office procedure video. The patient underwent a maxillary antrostomy and clearing of the sinus.

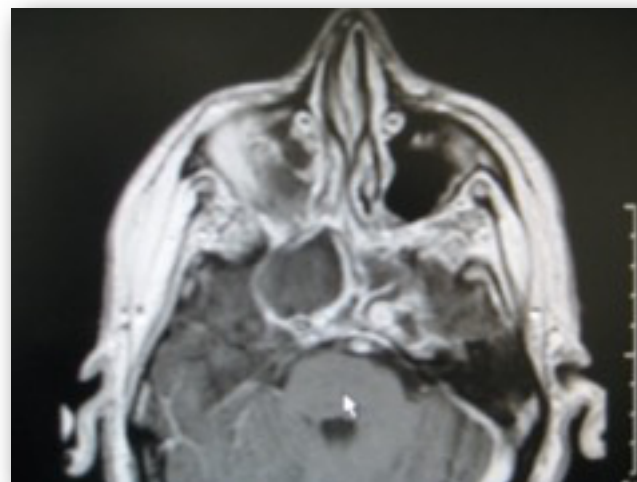
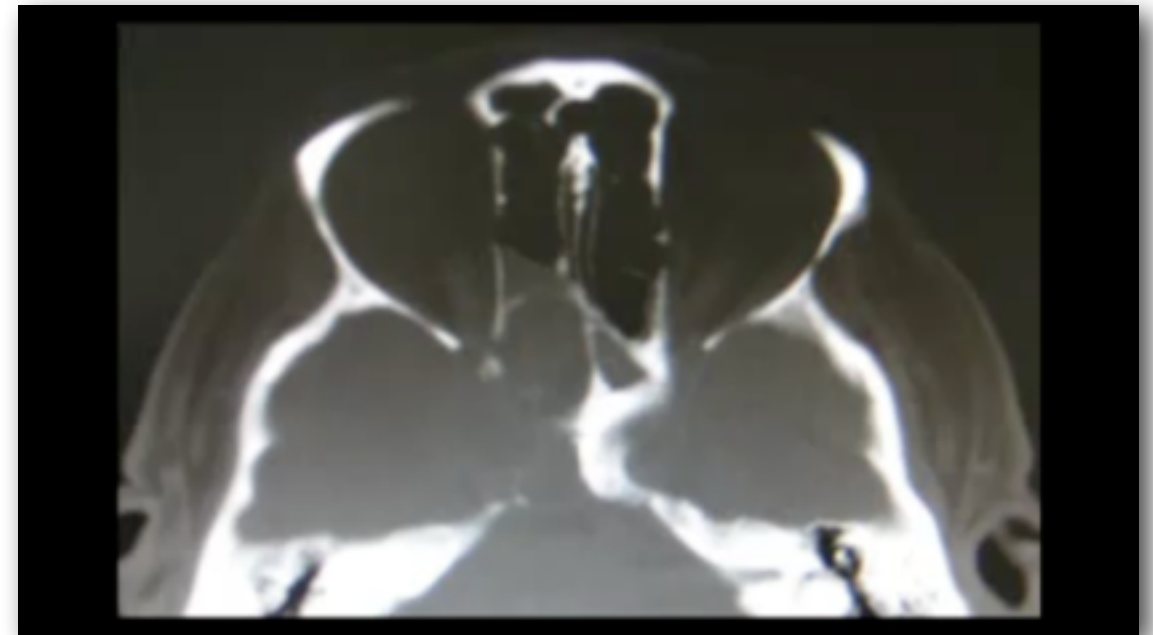
Secondary bacterial infection is commonly found with a fungus ball.



Sphenoid Fungus Ball

A 72-year-old man presented with a 1-month history of retro-orbital pain and decreasing vision. CT and MRI showed an opacified right sphenoid sinus with some bone erosion laterally. Due to the accessibility of the sphenoid sinus and the urgency of the symptoms, an office procedure was performed on the day of presentation.

Primary sphenoidotomy was performed under local anesthesia. Once the sphenoid sinus was accessed a fungus ball was encountered. After widening the sphenoidotomy, the fungus ball was extracted with suction and various instruments, including an otologic wax curette. After complete clearing of the sphenoid sinus contents, the pulsation of the internal carotid artery in the dehiscent lateral sphenoid wall can be seen. Instrumentation was not performed laterally due to the dehiscence, but the sphenoid could still be safely cleared of the fungus ball.



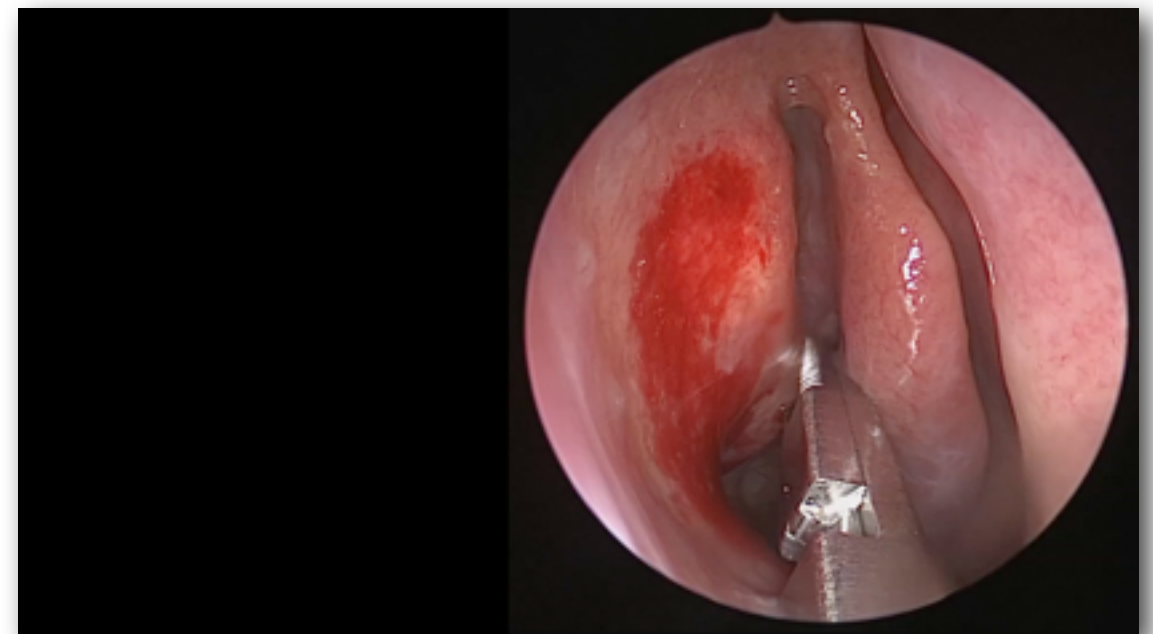
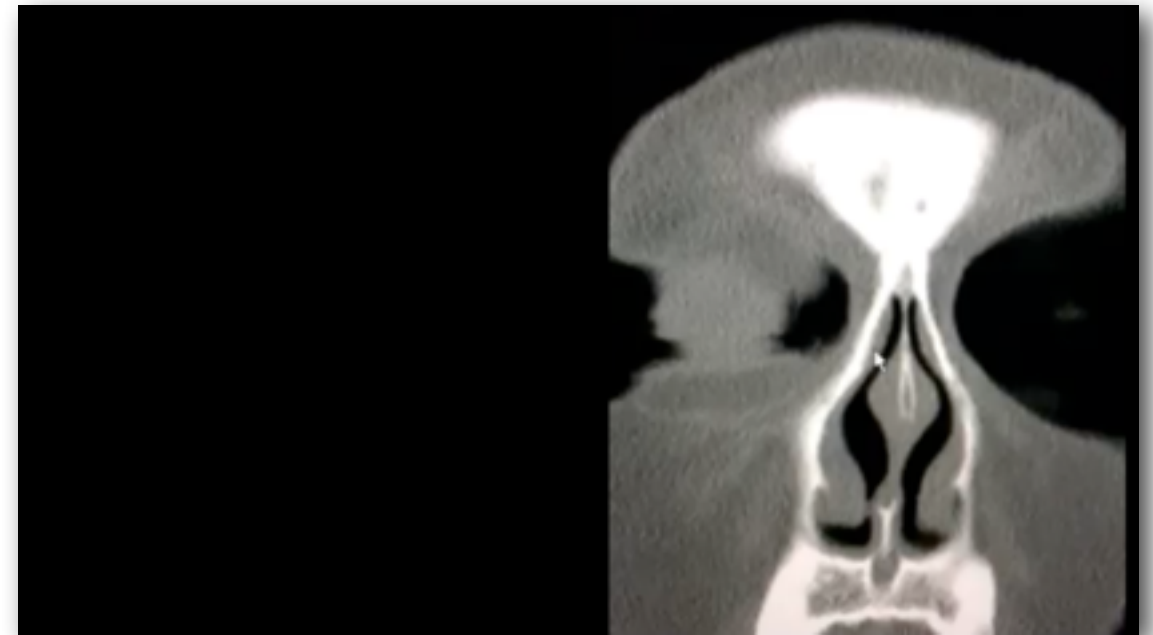
Chronic Rhinosinusitis after Medical Therapy

Primary sinus surgery can be safely performed in the office setting, especially for limited sinus disease. We have already seen this for fungus balls.

This is a 65-year-old man with right-sided nasal congestion and frontal pressure, which has not resolved with medical therapy.

CT scan shows right-sided anterior ethmoid, maxillary, and frontal sinus disease, with a large anterior ethmoid cell obstructing the frontal sinus.

In the office, under local anesthetic, this patient underwent a primary uncinectomy, anterior ethmoidectomy, and frontal sinusotomy. This video shows that the same procedure that would have been performed in the operating room was performed in the clinic.



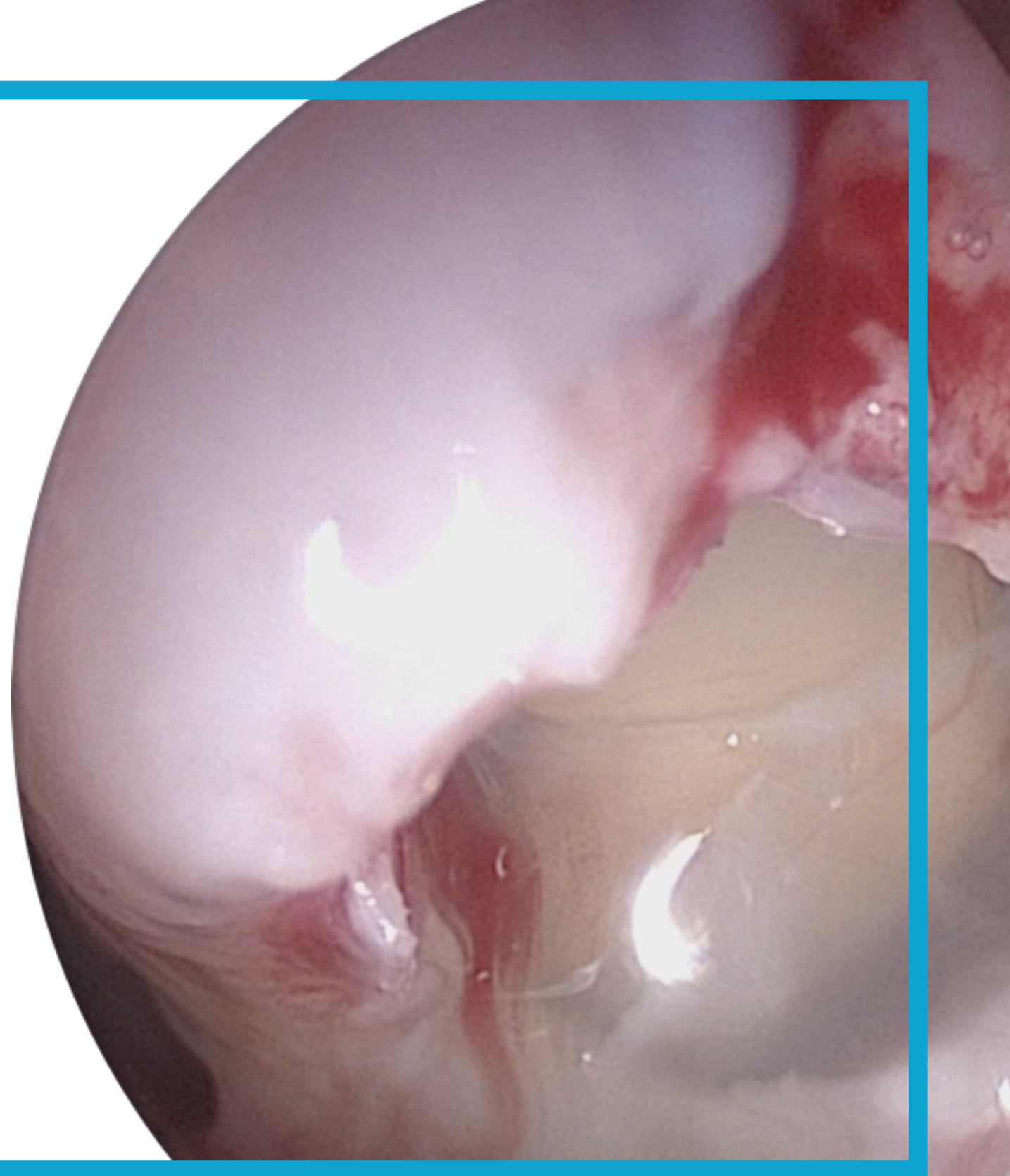
Mucocele

Answer the question & check your answer

Contraindications for office drainage of mucoceles are:

- ☐ A. Unoperated sinuses
- ☐ B. Orbital erosion
- ☐ C. Skull base erosion
- ☐ D. All of the above
- ☒ E. None of the above

Check Answer



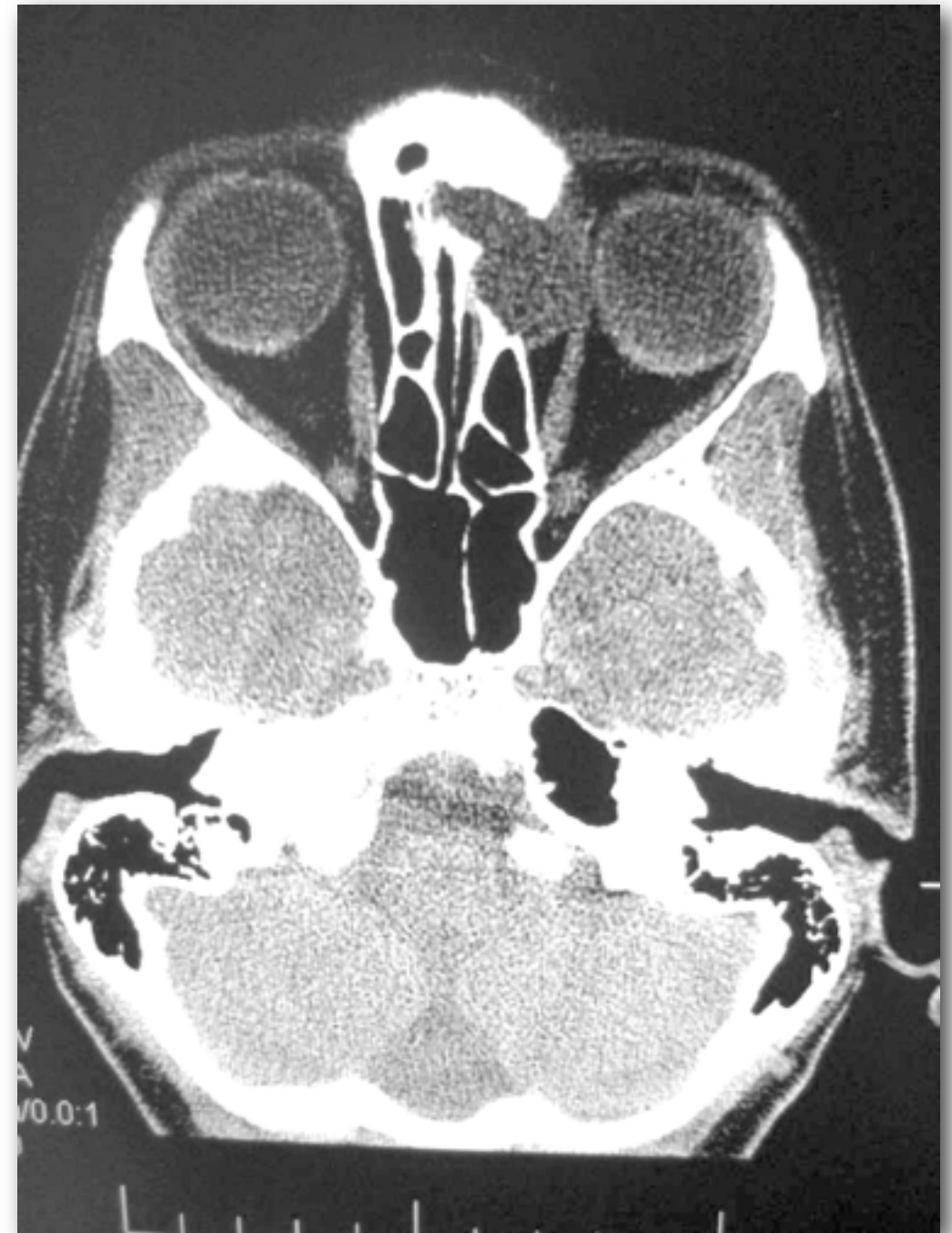
Sinus Mucoceles

A mucocele is an obstructed sinus cavity that is filled with mucus. Once the sinus cavity is completely filled, the increased pressure of the mucus will gradually expand the sinus walls and cause bone thinning and erosion, most commonly of the orbital walls.

Any sinus cavity can be involved but the most common are the frontal and ethmoid sinuses.

Treatment involves wide marsupialization of the mucocele cavity.

Mucoceles can occur in previously operated sinus cavities or primarily in unoperated patients.



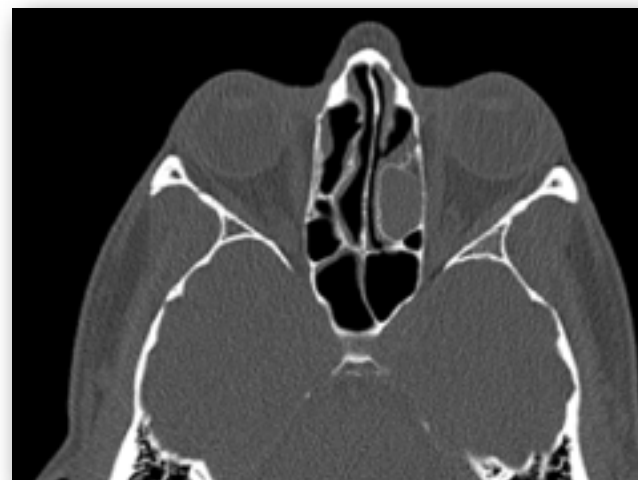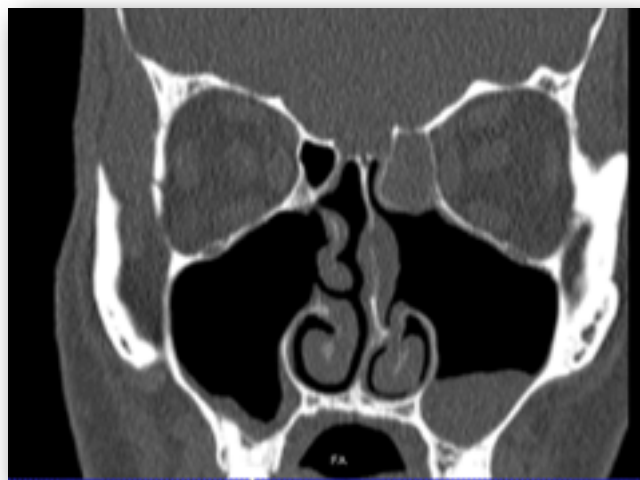
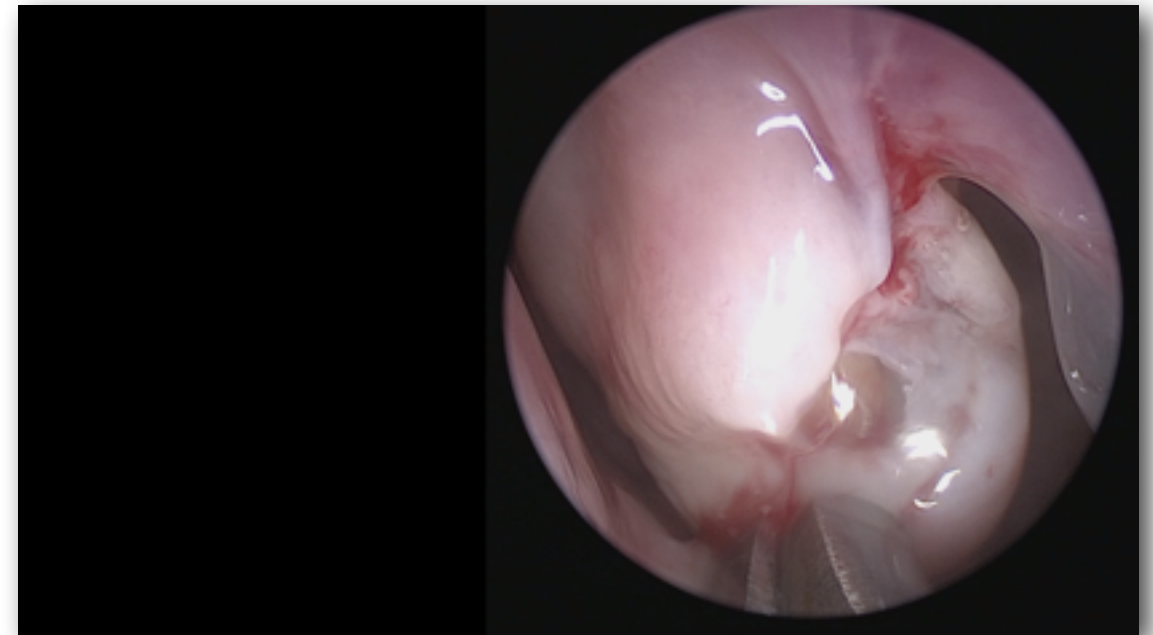
Ethmoid Mucocele

Mucocele in patients that have undergone previous sinus surgery are usually easier to treat due to the more open sinus cavities and easier access to the mucoceles.

This is the CT scan of a patient who had previous sinus surgery with subsequent development of an ethmoid mucocele.

This is a very straightforward case for office surgery.

This mucocele is easily identified and accessed due to the previous ethmoidectomy. The anterior and inferior walls are widely removed to marsupialize the mucocele cavity to minimize the chance of recurrence.

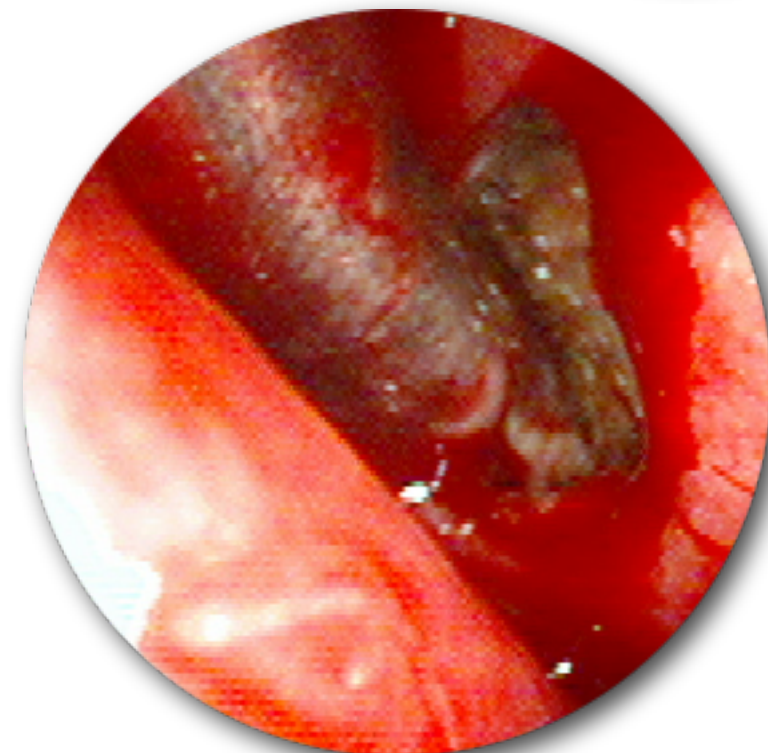
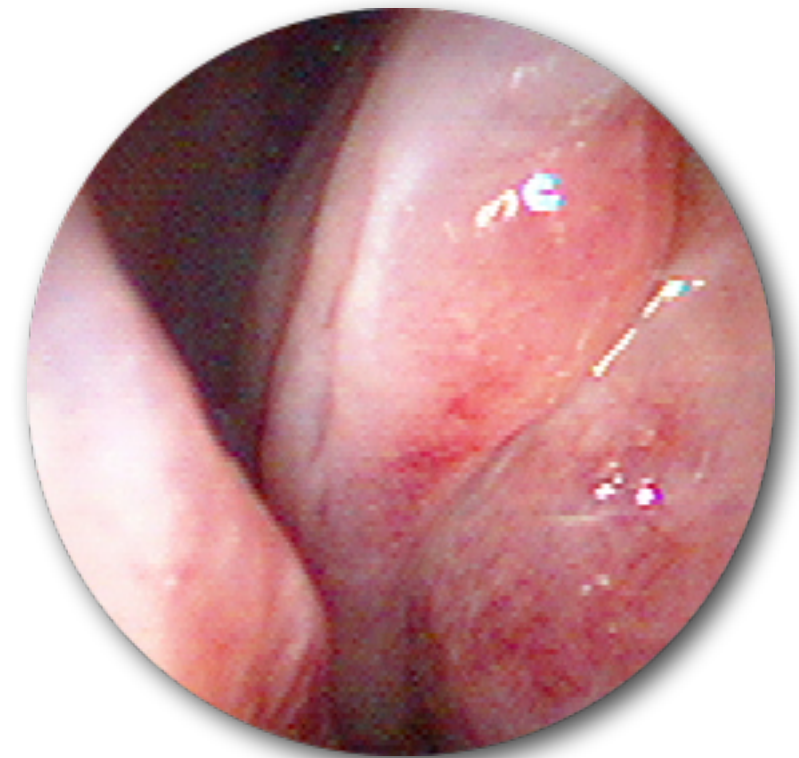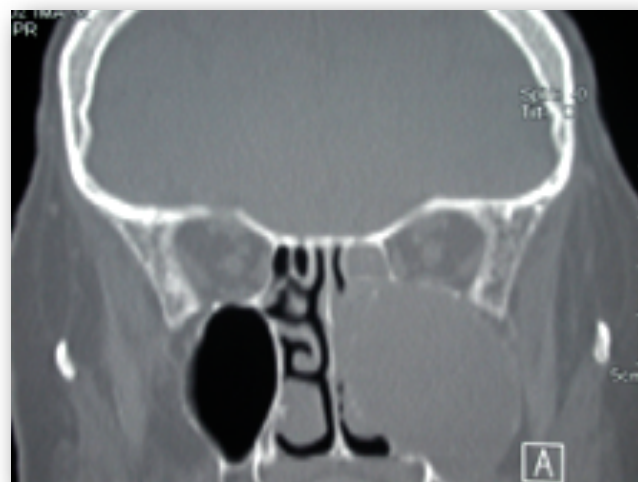

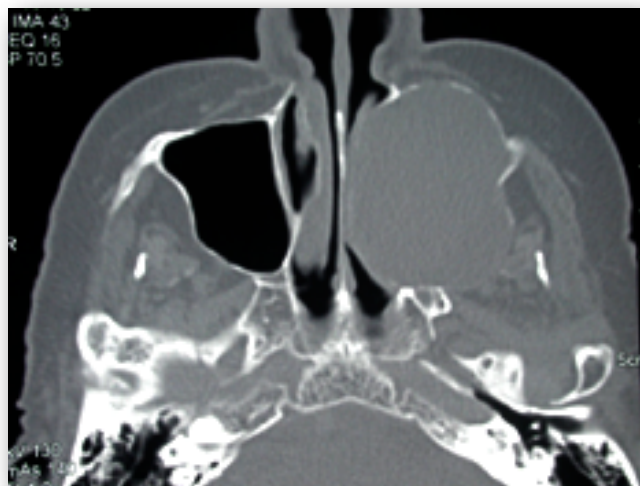
Large Maxillary Sinus Mucocele

An 80-year-old woman was referred with left facial bulging and concern for tumor.

The CT scan shows the left maxillary sinus to be expanded with a soft tissue process, with erosion of the medial and lateral walls. The endoscopic picture shows medial bulging of the inferior meatus.

This provides an easy path to open the maxillary sinus and evacuate the mucocele contents, thereby preventing the need to go to the operating room.

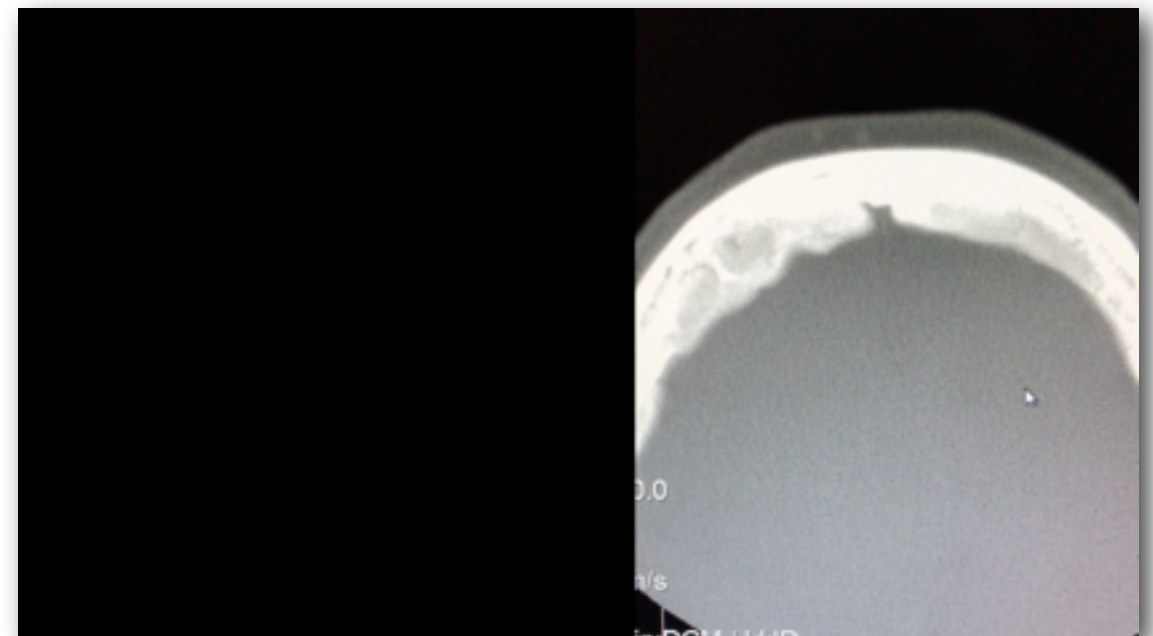

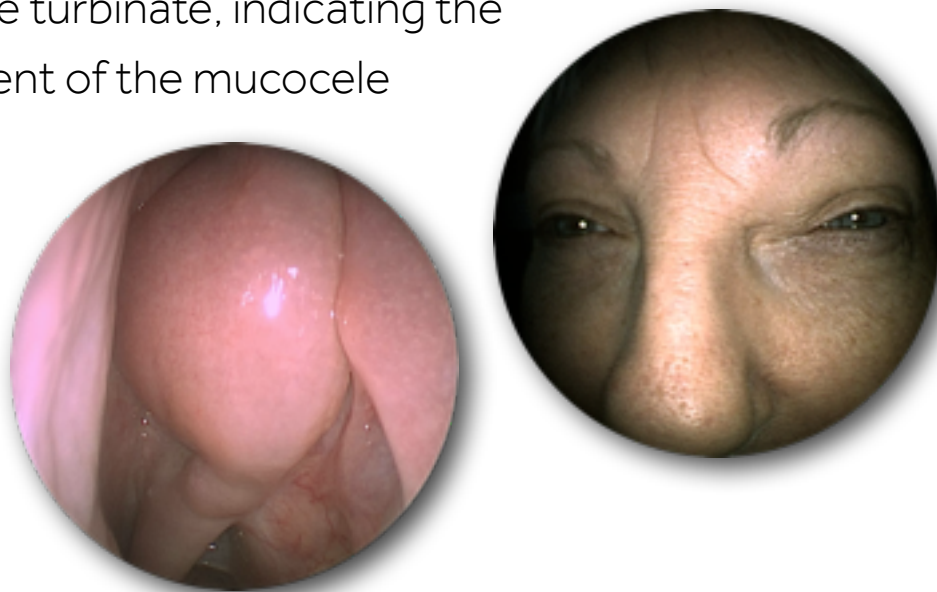


Frontal Mucocele after ESS

This is a 63-year-old woman who was referred with left-sided diplopia and headache. Physical exam showed a left medial upper eyelid fullness, and displacement of her globe laterally.

She had undergone ESS 10 years earlier. CT scan shows a large left frontal sinus mucocele with erosion of the medial orbital wall and expansion and thinning of the posterior frontal sinus wall. The right frontal sinus is also opacified but not expanded. It is not clear if there is a connection to the right frontal sinus through the intersinus septum.

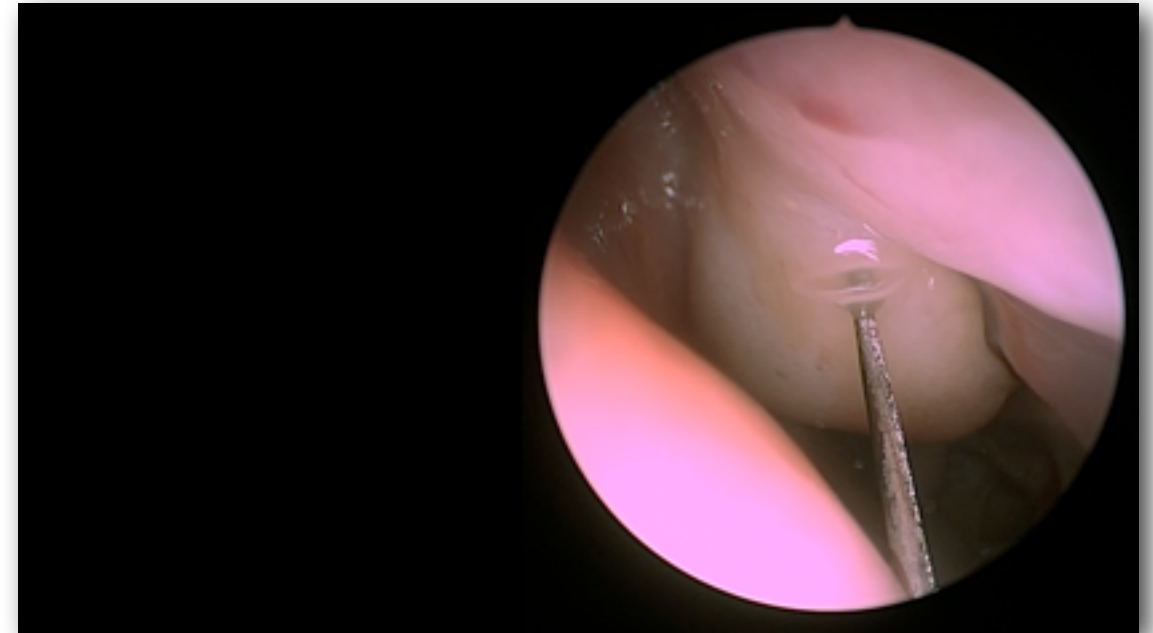
Endoscopic exam shows a fullness of the leading edge of the middle turbinate, indicating the anterior extent of the mucocele cavity.



Drainage of Frontal Mucocele

After topical anesthesia is administered, local anesthetic is injected into the middle turbinate. For superficial mucoceles, this is a safe way to identify the area to enter, as the mucus will exude through the needle tract, as shown in this video. Staying inferomedially provides safety by staying a maximum distance away from the areas of dehiscence, especially when the orbital contents are no longer under pressure and shift medially, and allows complete drainage of the mucocele.

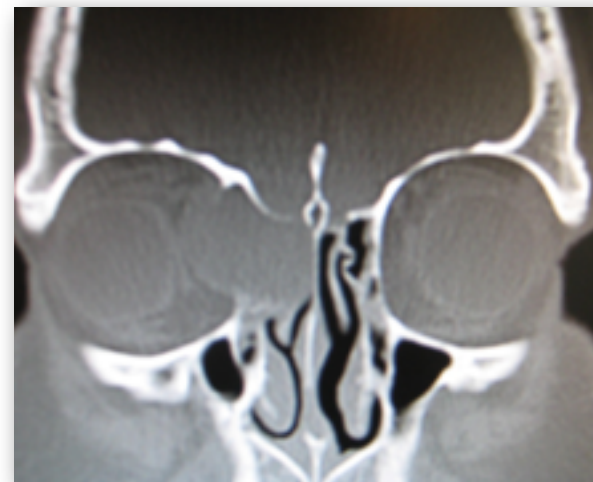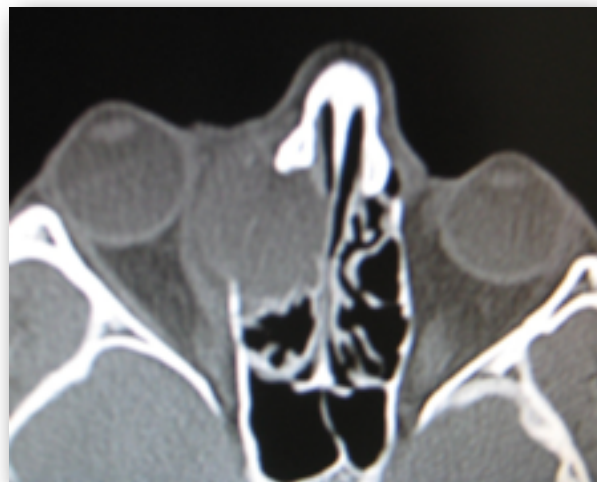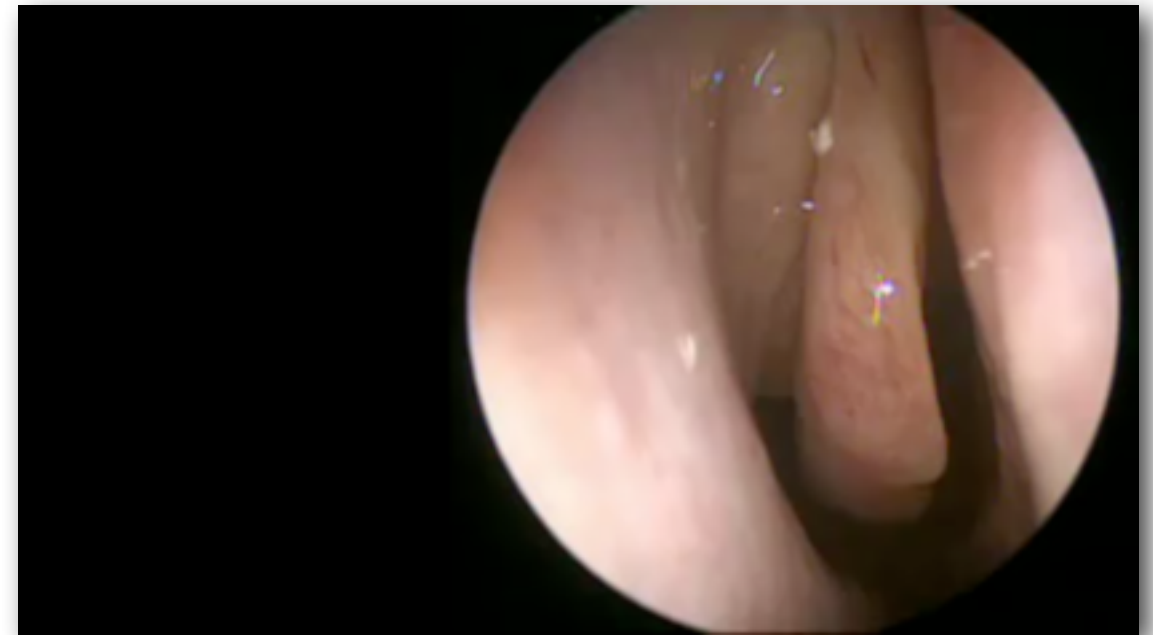Since bone erosion is commonly found with mucoceles, it is not a contraindication to office drainage. In this patient, the left frontal sinus was completely drained, and the orbital symptoms quickly resolved. The intersinus septum was not dehiscent, so the right frontal sinus mucocele was not drained with this procedure. A second procedure was required to drain the right frontal sinus.



Ethmoid Mucocele with Orbital Erosion

Mucoceles can occur in patients who have not had previous sinus surgery, as seen here in this patient with a right frontoethmoid mucocele with orbital erosion and lateral displacement of the globe.

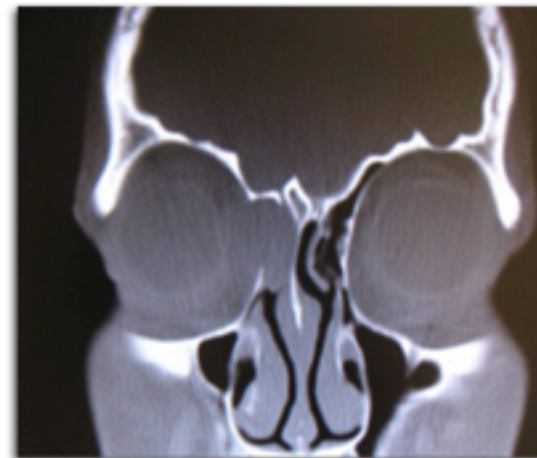
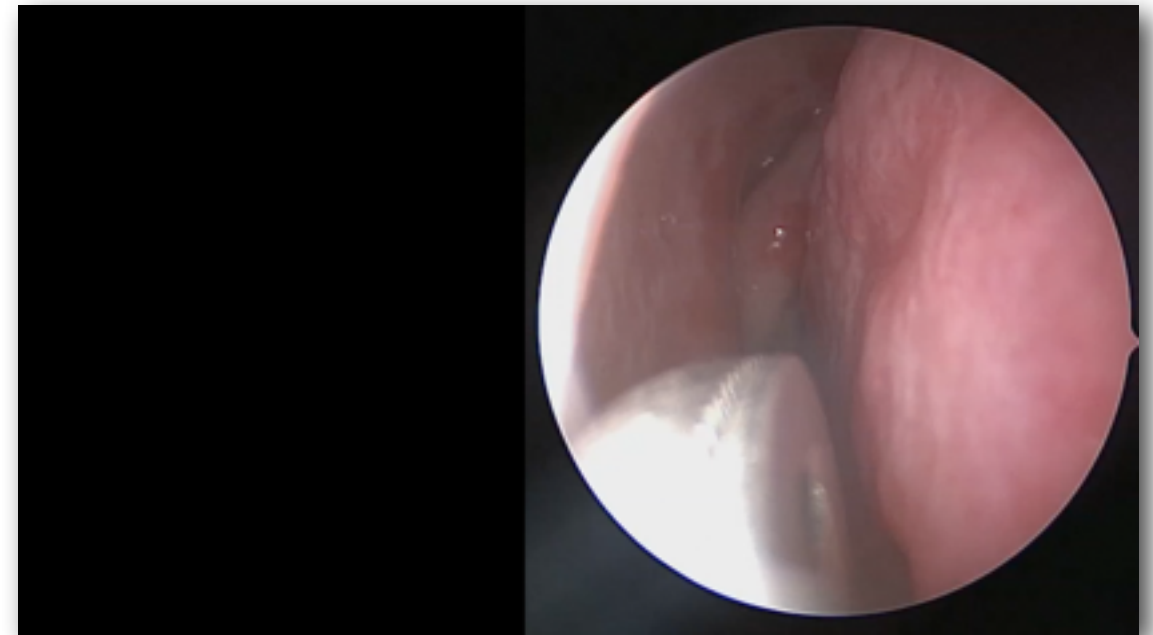
Primary surgery is performed, including a superior uncinectomy and anterior ethmoidectomy. After the mucocele cavity is cleared the dehiscent orbit can be seen in relief.



Primary Frontal Sinusotomy with Partial Middle Turbinate Resection for Mucocele

This CT image and video show an example of a patient who has not undergone previous ESS, and presented with a frontoethmoid mucocele with orbital erosion. The septum is deviated to the side of the mucocele, making access more difficult. In this situation, a partial resection of the upper middle turbinate allows access to the agger nasi and frontal recess.

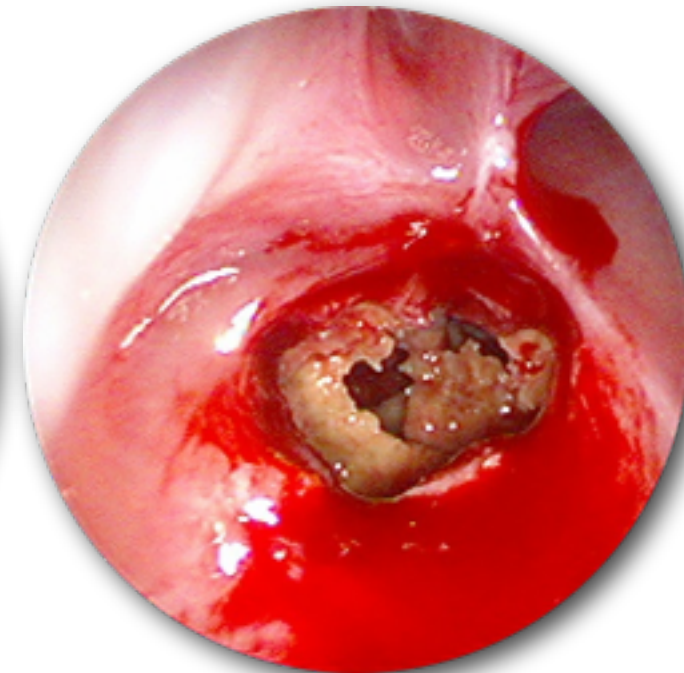
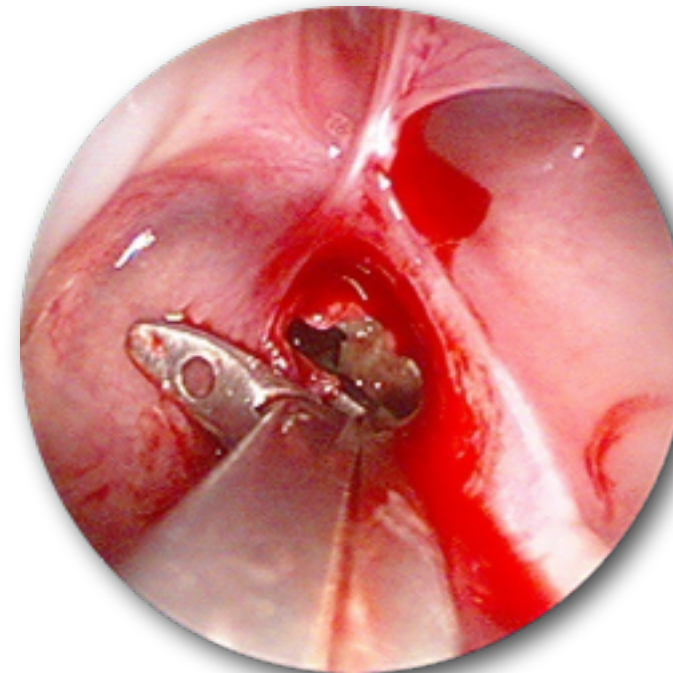
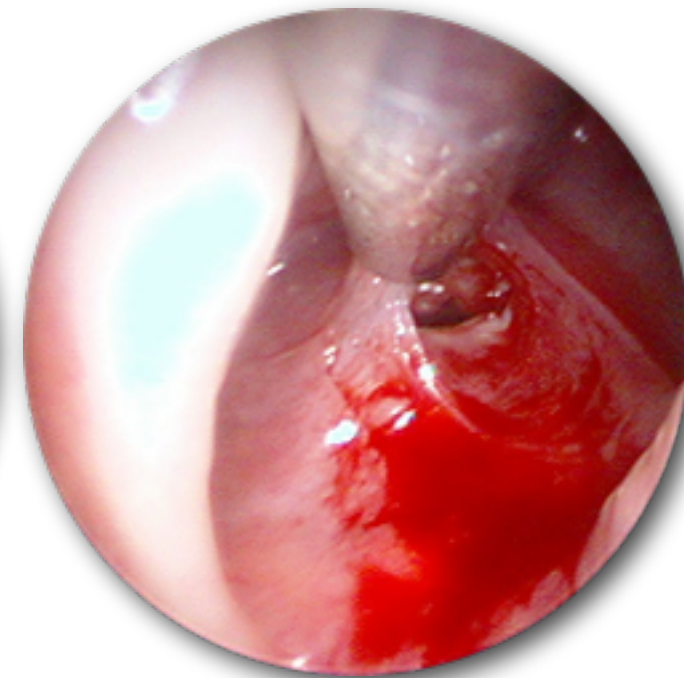
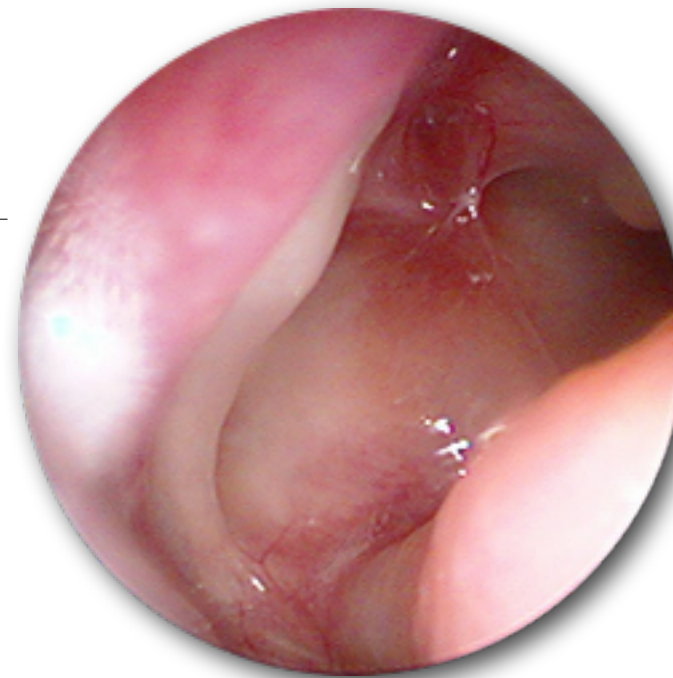
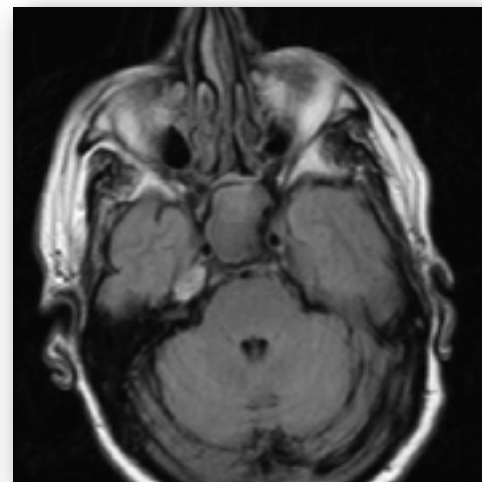
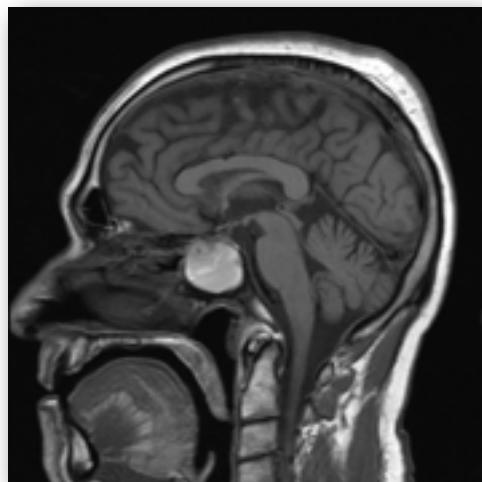
The mucocele can then be more easily accessed and drained. After complete drainage the dehiscent orbit is easily visualized with gentle palpation on the patient's globe. Despite the orbital dehiscence, the procedure can be safely performed by not dissecting laterally until visualization is good.



Sphenoid Mucocele after Trans-Sphenoidal Pituitary Surgery

This patient had previously undergone a TSA, and developed retro-orbital headaches.

MRI shows infected fat vs. mucocele or fungus ball. The patient underwent sphenoidotomy and evacuation of the infected fat/mucocele in the office, as seen here.



Literature

Barrow and DelGaudio reported a retrospective study of 31 patients undergoing office drainage of 35 mucocoeles5.

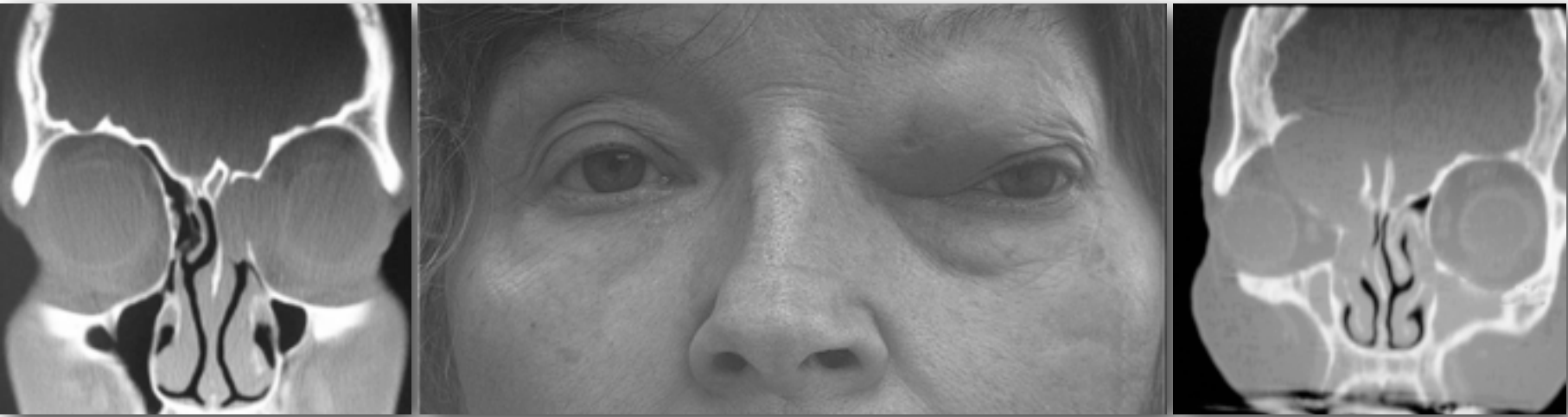
All 35 mucocoeles were successfully accessed in the office. 32 mucocoeles (91%) were completely drained in the office, while 3 required additional surgery due to the presence of septations resulting in incomplete drainage.

There were no procedural complications.

At 15-months mean follow-up, there was recurrence of 2 mucocoeles (5.7%). All but 1 patient said they would undergo in-office drainage again over drainage in the operating room. The results show the distribution of mucocoeles, with the frontal and anterior ethmoid sinuses

	OUR STUDY	PREVIOUS STUDIES
Frontal	12 (34%)	28 – 62%
Anterior Ethmoid	11 (31%)	38%
Posterior Ethmoid	6 (17%)	12%
Maxillary	4 (11%)	6 – 22%
Sphenoid	2 (6%)	5 – 11%
Bone Erosion		
Total	18 (51%)	42 – 53%
Orbital	16 (46%)	20 – 35%
Skull Base	7 (20%)	6 – 15%

being the most common locations. Over 50% of patients had bone erosion, with most having orbital erosion, and 20% having skull base erosion.

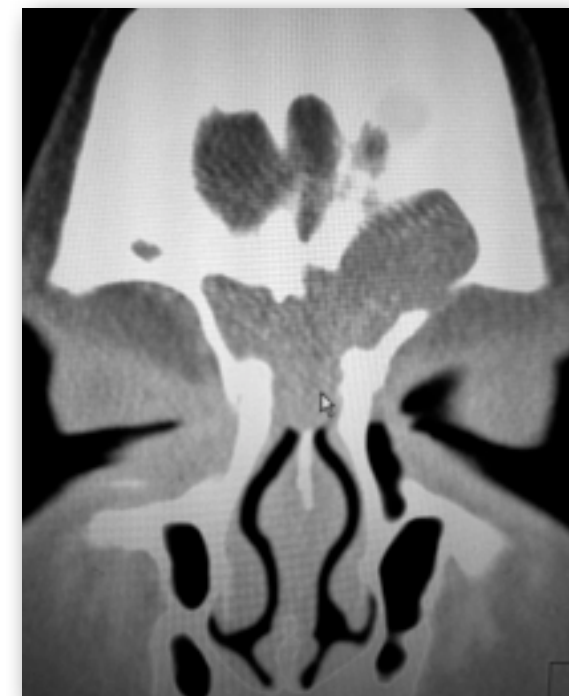
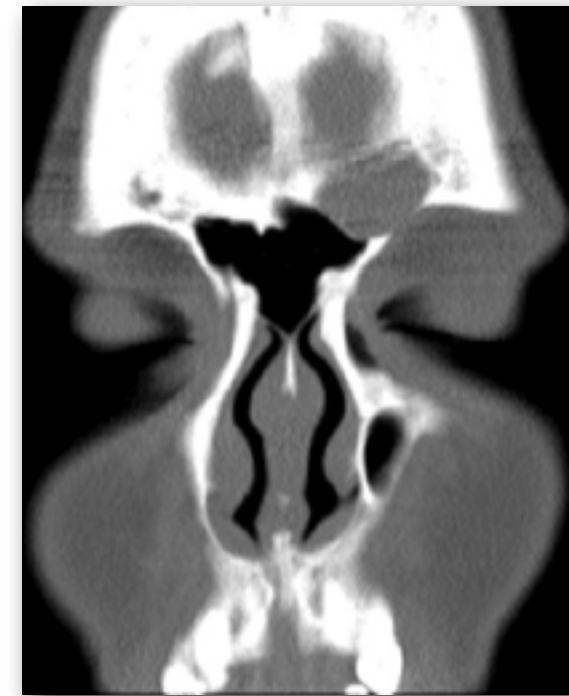
Relative Contraindications to Office Drainage of Mucocoeles

Patients with mucocoeles that have septations that are not accessible in the office may not have successful complete drainage.

This CT scan is an example of a patient that had successful office drainage of a mucocoele, but a superolateral loculation could not be reached and drained due to a bony septation. Subsequent surgery in the operating room was required to completely clear the residual mucocoele.

Neo-osteogenesis is also a relative contraindication, depending on the extent of bone formation. In this study, 3 patients with neo-osteogenesis were able to tolerate the procedure in the office. One procedure was aborted due to significant bone thickening and the amount of force needed to get through the bone.



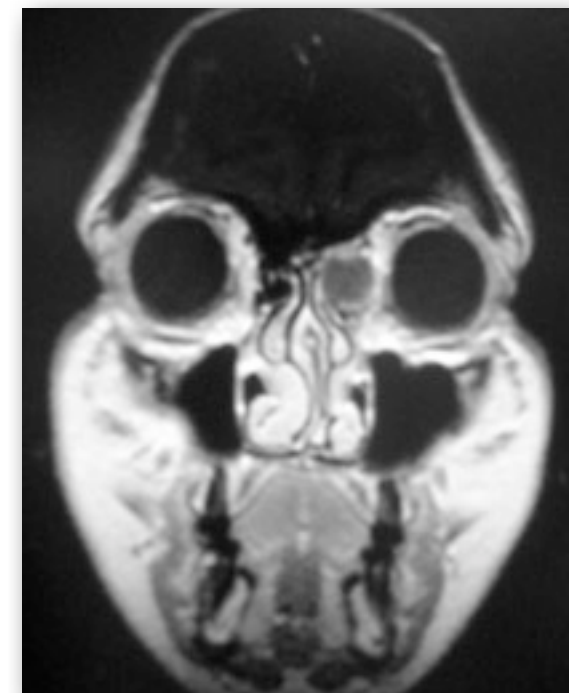
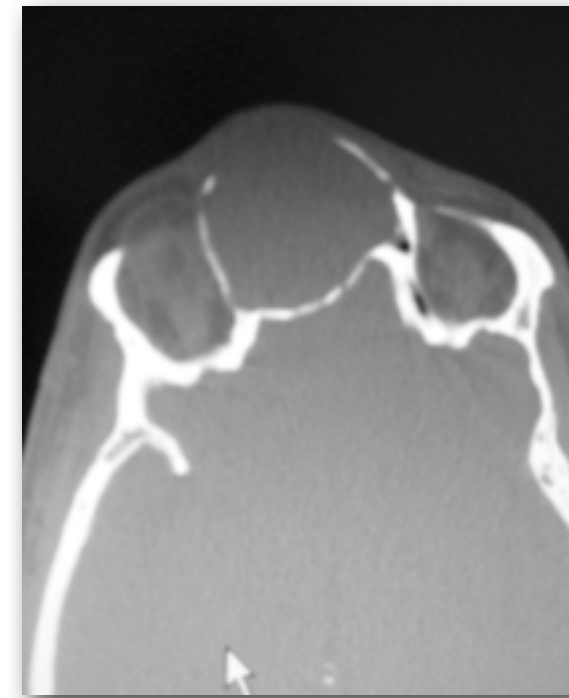
Conclusions

In-office drainage of sinus mucocoeles have success rates comparable to that of drainage in the operating room.

This can be performed whether or not the patient has had previous ESS.

Orbital and skull base bone erosion are not contraindications to in-office drainage.

Significant neo-osteogenesis and compartmentalized mucocoeles are relative contraindications.

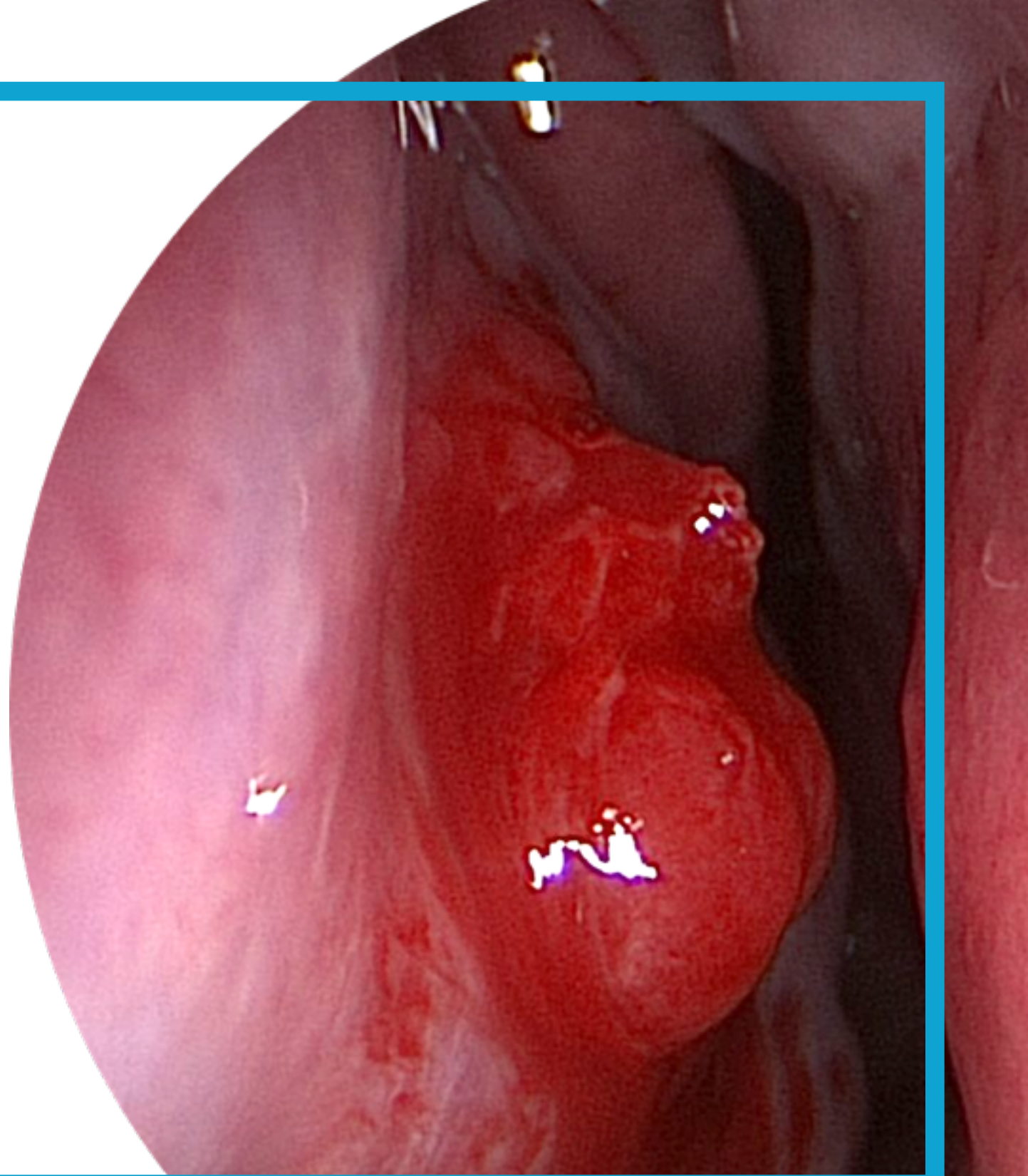


Masses

Answer the question & check your answer

Office surgery is appropriate for removal of all of the following except:

- ☐ A. Primary benign tumors
- ☐ B. Recurrent benign tumors
- ☒ C. Malignant tumors
- ☐ D. Nasal septal lesions



Click

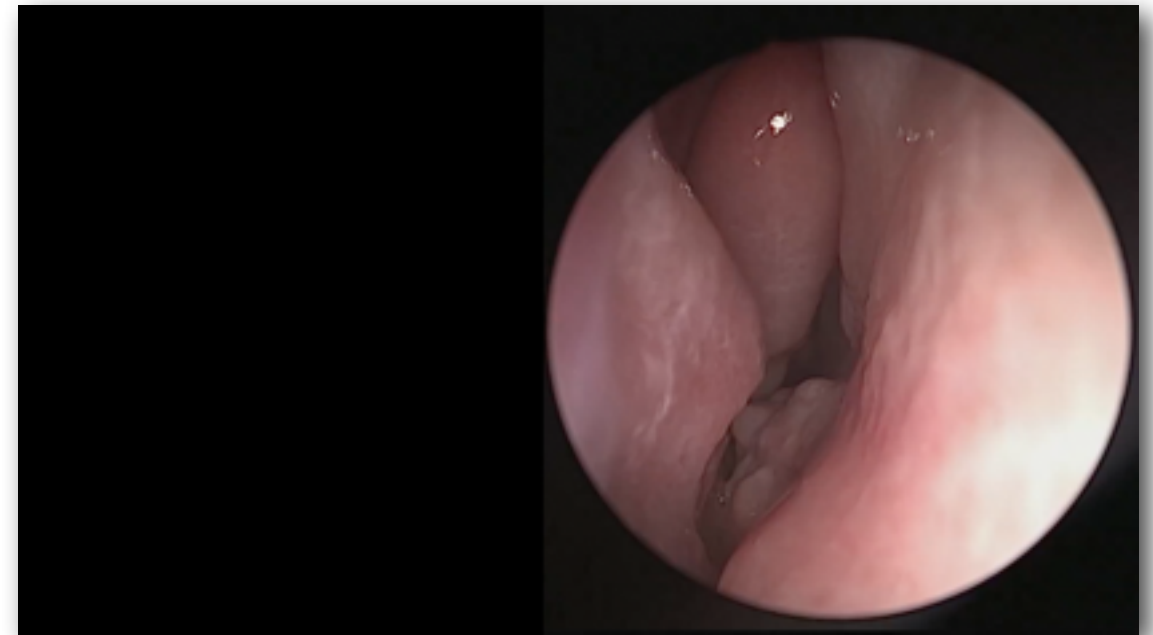
Check Answer

Nasal Septal Mass Excisional Biopsy

This is a natural extension of the procedures that we all perform as rhinologists, such as endoscopic biopsy. Complete removal of masses can be performed with smaller lesions that are accessible.

This man presented with right-sided nasal congestion. Nasal endoscopy revealed a 1 cm papillary appearing mass on the inferior nasal septum. Rather than perform an incisional biopsy, complete excision of the lesion was performed.

The pathology was consistent with an inflammatory polyp. Had the pathology shown inverted papilloma, a wider excision would have been subsequently performed.

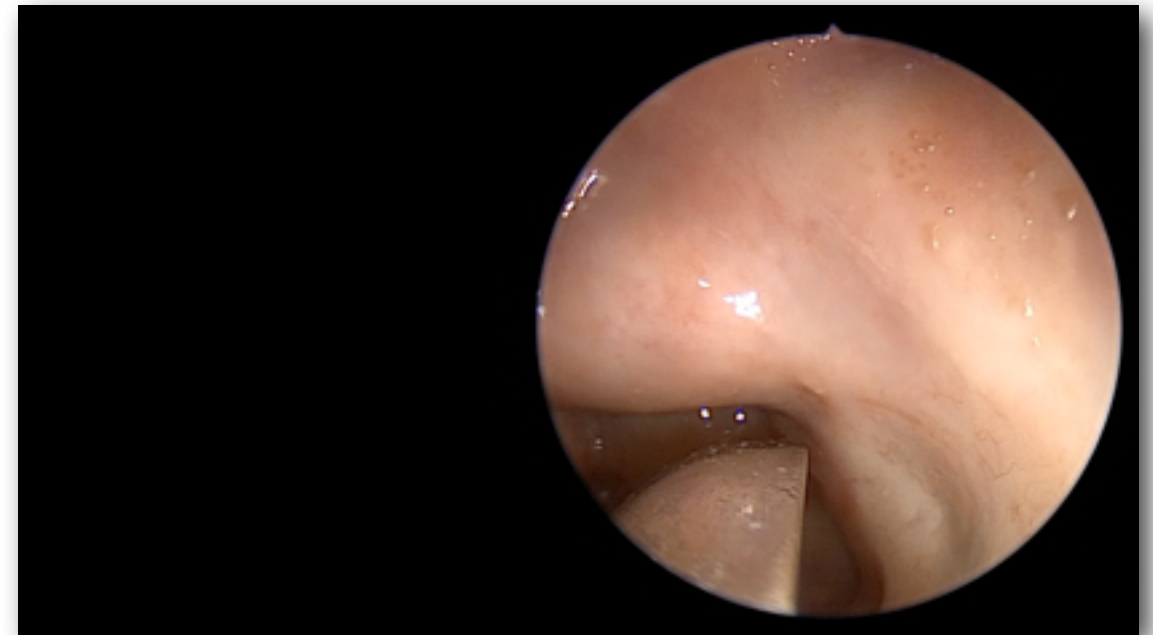


Office Resection of Focal Recurrence of Sphenoid Inverted Papilloma

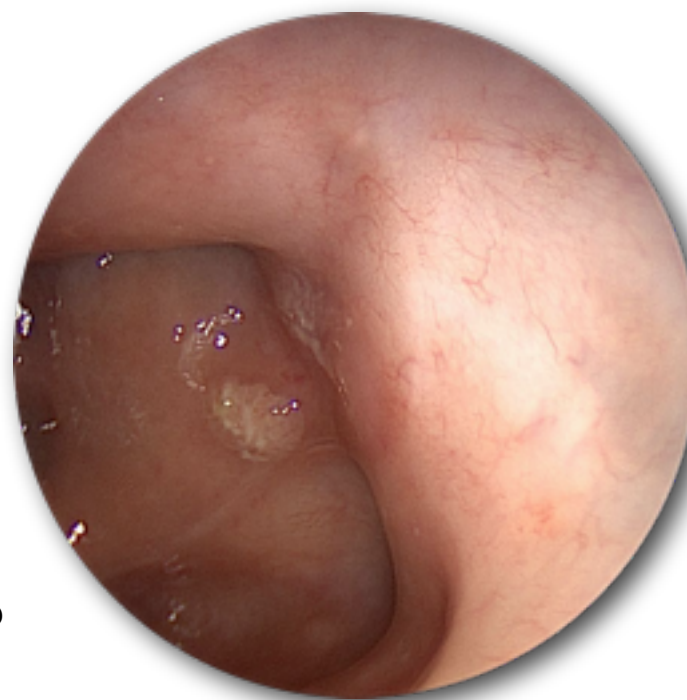
Small recurrences of benign tumor can be addressed in the office when the lesions are accessible.

In this case, a small recurrent inverted papilloma was identified in the posterosuperior wall of the left sphenoid sinus. This was easily resected in the office, as shown in this video.

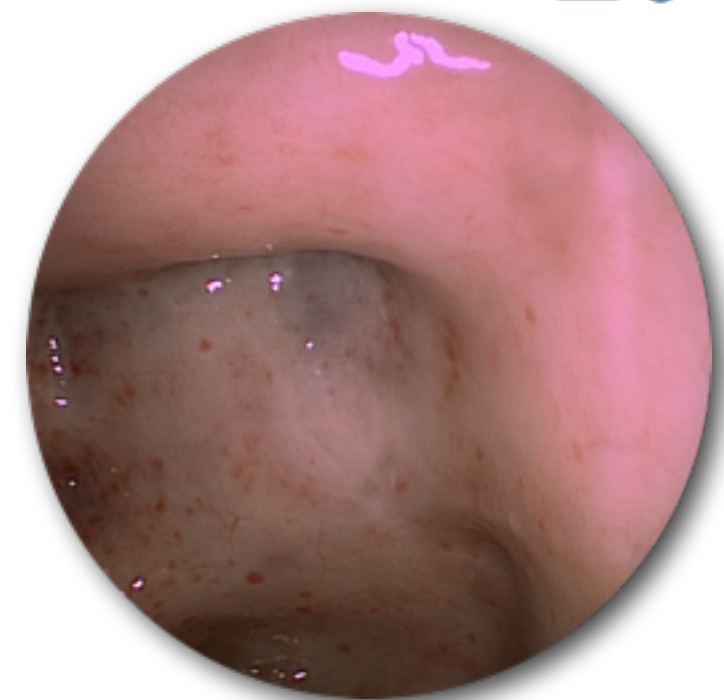
The patient has remained free of disease for 6 years.



preop



2 years postop



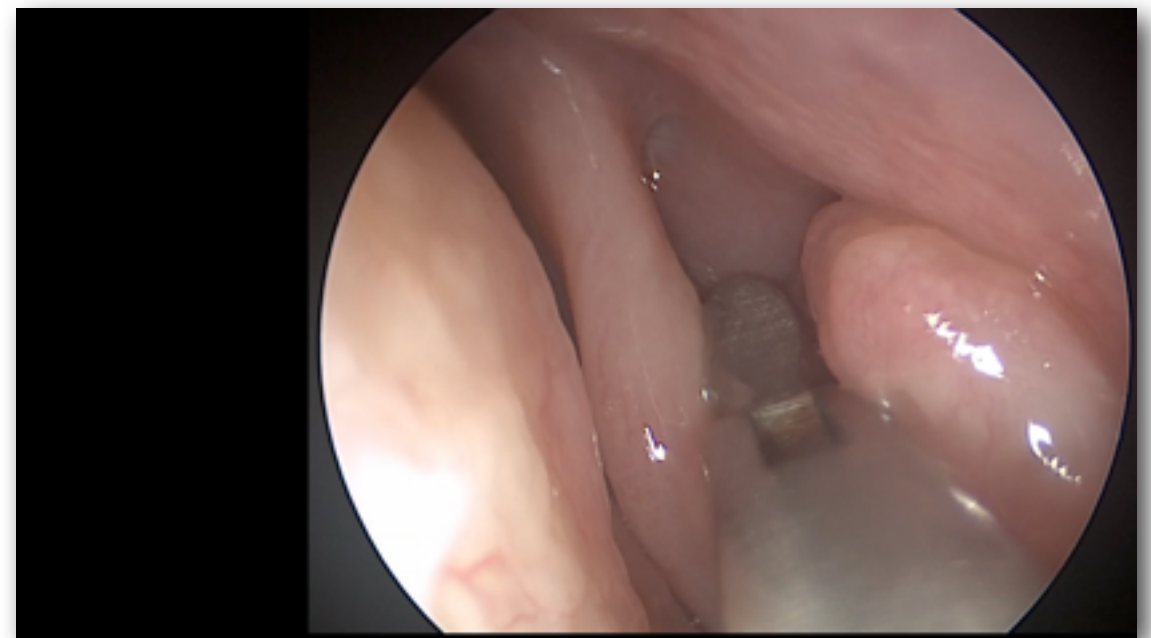
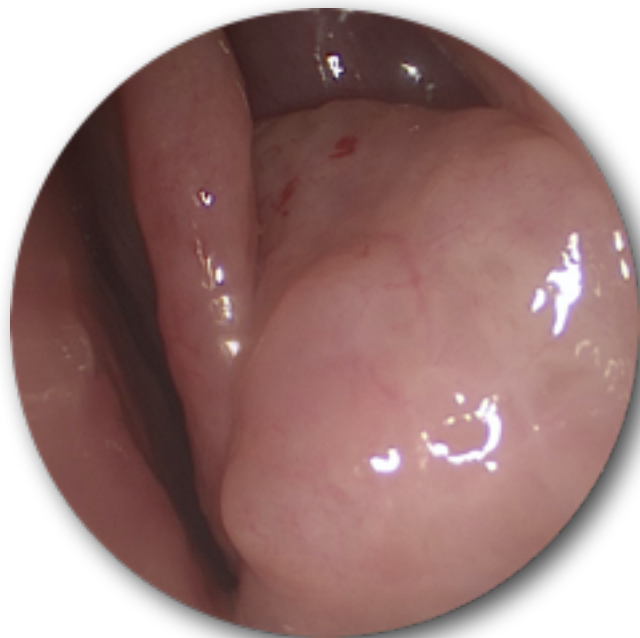
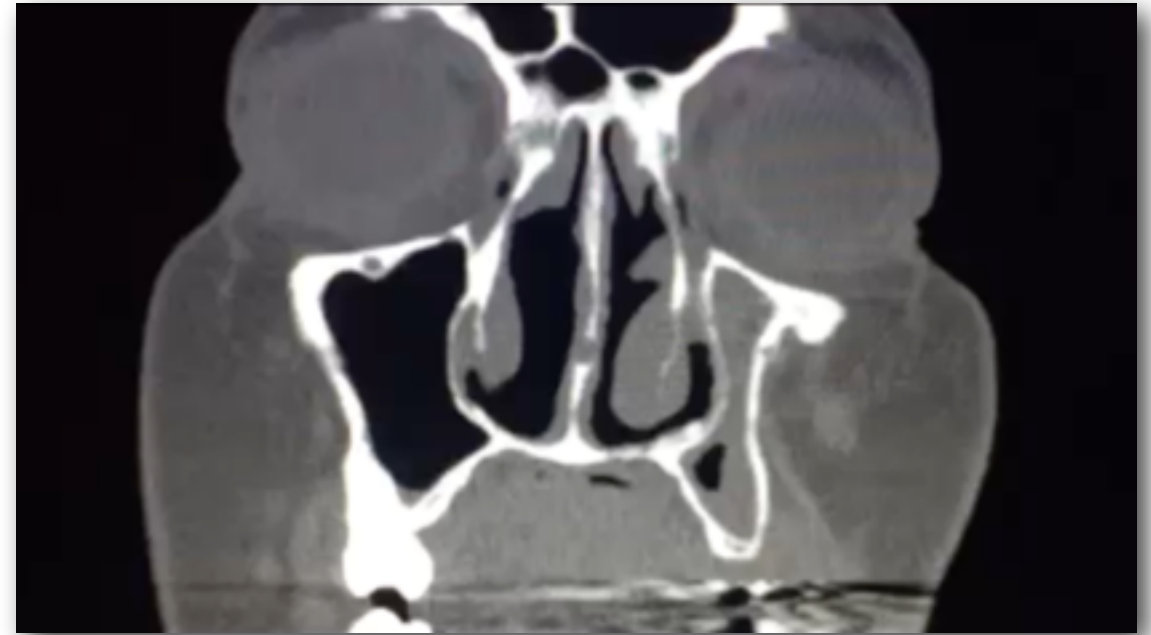
Middle Meatal Tumor

A 67-year-old woman presented with left greater than right nasal congestion. She had a history of seasonal allergies.

Nasal endoscopy showed a left middle meatal papillary lesion suspicious for inverted papilloma. (photo below)

CT scan showed a left middle meatal soft tissue mass obstructing the maxillary outflow tract but not involving the maxillary sinus or ethmoids.

An office biopsy was performed which confirmed inverted papilloma. (video)

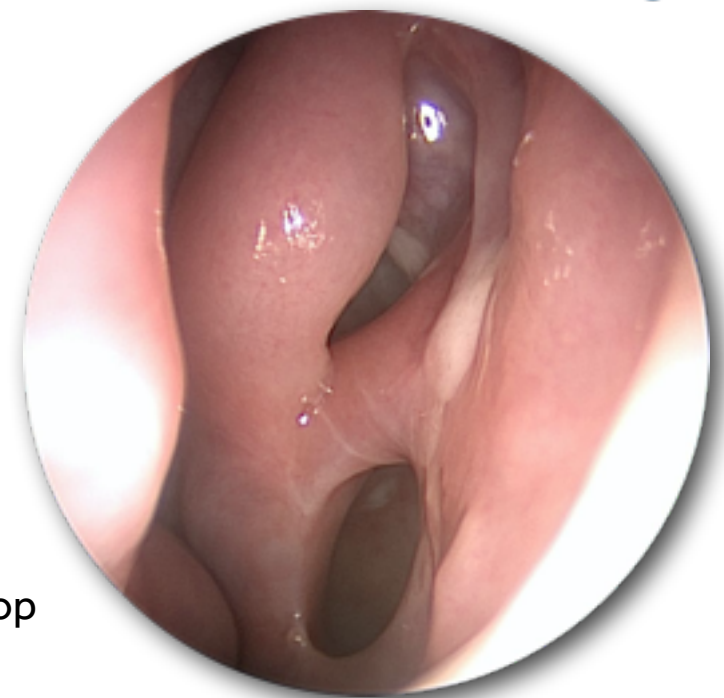
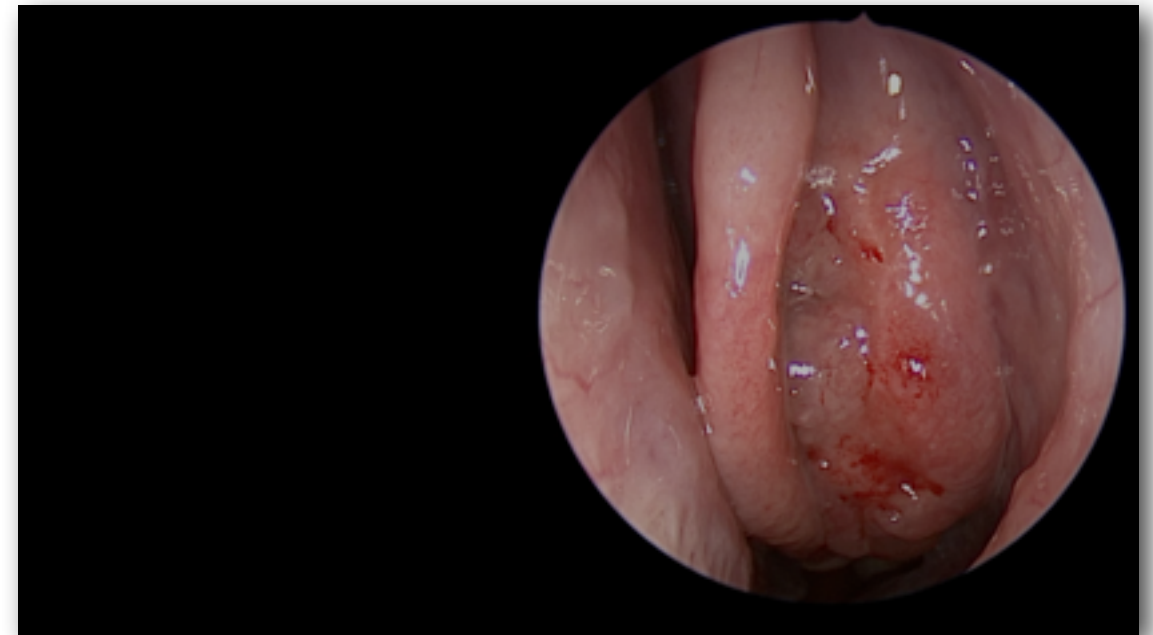


Office Resection of Primary Inverted Papilloma

Because of the limited involvement of the tumor, office resection was performed under topical and local anesthesia.

A maxillary antrostomy was performed first to confirm that the maxillary sinus was clear. An uncinectomy was then performed and the tumor was freed from the ethmoid bulla. An anterior ethmoidectomy was performed, demonstrating no ethmoid involvement. Finally the attachment to the posterior medial wall of the maxillary sinus was resected to remove the tumor en-bloc, completing the resection.

An eight-month postoperative endoscopic picture shows no evidence of recurrence.



8 months postop

POST PROCEDURE CARE

Follow up &
Conclusions



Medtronic
Further, Together

Follow up &

Postoperative care for office surgery should be the same as for procedures performed in the operating room.

Nasal saline irrigations with or without topical steroids are a mainstay of postoperative care.

Extensive polypectomy may require systemic steroids in the immediate postoperative period, as these patients frequently have significant postoperative mucosal edema.

Routine follow-up and debridements should be performed to obtain the best outcome.

Conclusions

Office surgery is the next frontier of Rhinology.

- Appropriate patient and pathology selection is critical
- High patient satisfaction
- Shorter recovery
- Less missed time from work
- Lower cost to the healthcare system
- No anesthesia or OR fees
- Only perform procedures that are within your comfort zone

ADDENDUM

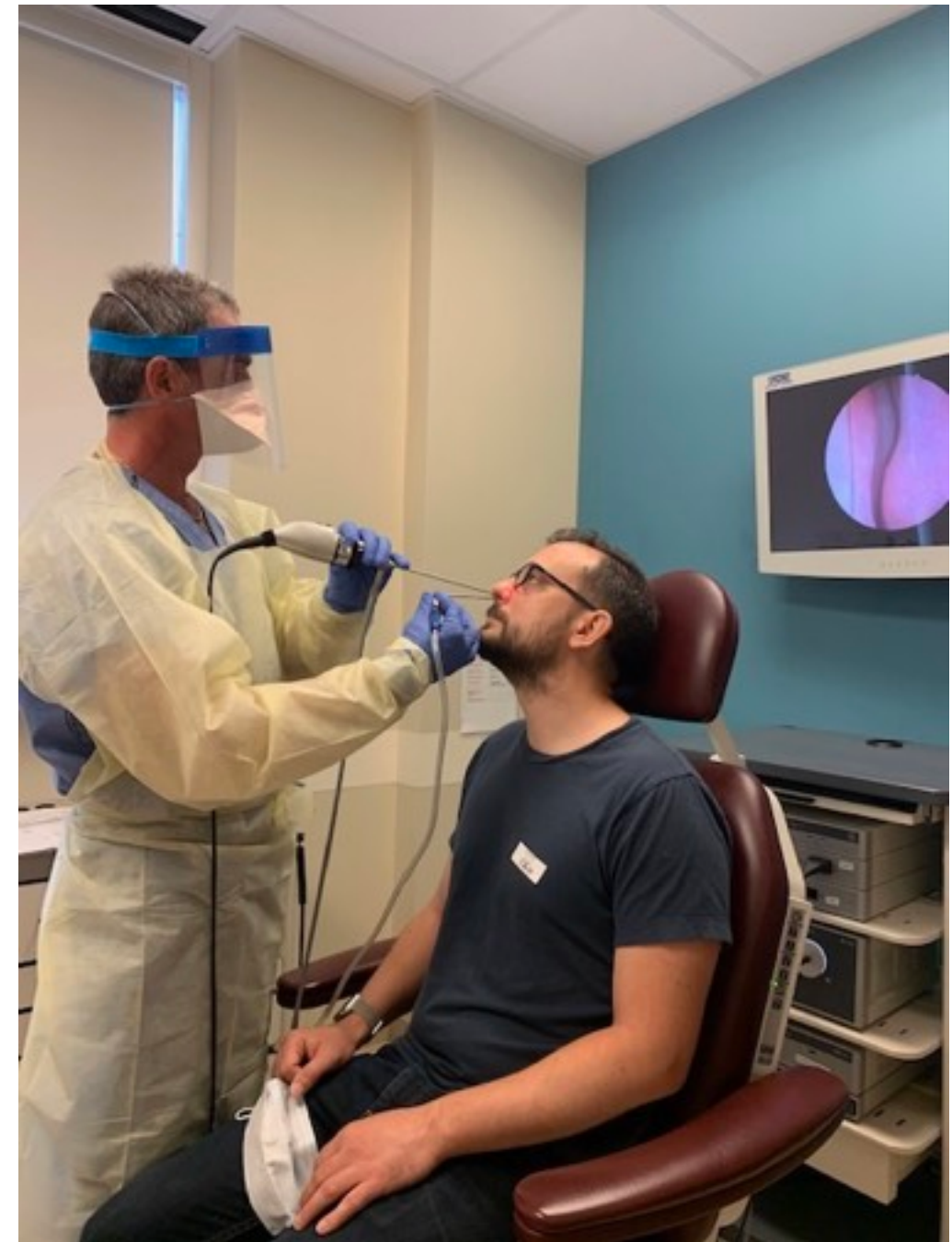Special considerations
COVID 19
References










COVID-19

During the Covid-19 pandemic novel rules and regulations have been introduced to maintain staff and patient safety. Personal precautions should conform to both local healthcare regulations and national ENT society guidelines when and where office surgery is undertaken.

In this photo appropriate PPE for Covid-19 protection is being used, including an N95 mask, face shield, and gown. The patient also has a protective mask that is removed during the procedure. Patient masks through which endoscopy can be performed to limit aerosol transmission can be used.



References

1. Lee JT, DelGaudio J, Orlandi RR.
Practice Patterns in Office-Based Rhinology: Survey of the American Rhinologic Society.
Am J Rhinol Allergy. 2019 Jan;33(1):26-35. 
2. Zara M. Patel, Sarah K. Wise, John M. DelGaudio
Office-Based Rhinology: Principles and Techniques
Plural Publishing Inc 2013;
Har/DVD edition (January 1, 1707)
3. Prickett KK, Wise SK, DelGaudio JM.
Cost analysis of office-based and operating room procedures in rhinology.
Int Forum Allergy Rhinol. 2012 May-Jun;2(3):207-11. 
4. DelGaudio JM, Ochsner MC.
Office surgery for paranasal sinus recirculation.
Int Forum Allergy Rhinol. 2015 Apr;5(4):326-8. 
5. White LJ, Rotella MR, DelGaudio JM.
Polypoid changes of the middle turbinate as an indicator of atopic disease.
Int Forum Allergy Rhinol. 2014 May;4(5):376-80. 
6. Hamizan AW, Christensen JM, Ebenzer J, Oakley G, Tattersall J, Sacks R, Harvey RJ.
Middle turbinate edema as a diagnostic marker of inhalant allergy.
Int Forum Allergy Rhinol. 2017 Jan;7(1):37-42. 
7. Brunner JP, Jawad BA, McCoul ED.
Polypoid Change of the Middle Turbinate and Paranasal Sinus Polyposis Are Distinct Entities.
Otolaryngol Head Neck Surg. 2017 Sep;157(3):519-523. 
8. DelGaudio JM, Loftus PA, Hamizan AW, Harvey RJ, Wise SK.
Central compartment atopic disease.
Am J Rhinol Allergy. 2017 Jul 1;31(4):228-234. 



Click

9. Hamizan AW, Loftus PA, Alvarado R, Ho J, Kalish L, Sacks R, DelGaudio JM, Harvey RJ.

Allergic phenotype of chronic rhinosinusitis based on radiologic pattern of disease.

Laryngoscope. 2018 Sep;128(9):2015-2021.

10. Barrow EM, DelGaudio JM.

In-office drainage of sinus Mucocoeles: An alternative to operating-room drainage.

Laryngoscope. 2015 May;125(5):1043-7.

Medtronic

Medtronic plc

ENT

6743 Southpoint Drive N
Jacksonville, FL 32216
USA

Toll free: (800) 874 - 5797

Telephone: (904) 296 9600


Fax: (800) 678 3995

© 2021 Medtronic.

All rights reserved. Photos and videos owned by
John M. DelGaudio, MD, FACS, FARS used by permission.

Medtronic, Medtronic logo and Further, Together are trademarks of Medtronic.
All other brands are trademarks of a Medtronic company.
UC202107676EN

OFFICE-BASED
RHINOLOGIC
SURGERY
MEDICAL EDUCATION



John M. DelGaudio, MD, FACS, FARS

Vice Chair
Professor of Otolaryngology
Chief of Rhinology and Skull Base Surgery
Director Emory Sinus, Nasal & Allergy Center
Emory University

Medtronic
Further, Together