

“Treatment of Type II Endoleaks With Ethylene-Vinyl-Alcohol Copolymer (Onyx)”

Massis K et al., 2012



Highlights:

1. Single center, retrospective study
2. 95 patients
3. Endoleaks treated with Onyx™
4. Median follow-up: 15 weeks
5. Decrease/stabilization of aneurysm sac size in 73.6% endoleaks; 34.0% overall residual endoleak rate

Background

- Endoleaks - defined as persistent blood flow into the aneurysmal sac - are the most common complication associated with endovascular aneurysm repair (EVAR).
- The most prevalent type of endoleak is the type II, where there is persistent flow into the aneurysm sac from one or more collateral vessels.
- There is some controversy regarding the optimal management of type II endoleaks and a variety of treatment techniques have been employed, including laparoscopic ligation of the inferior mesenteric artery or lumbar arteries, transarterial coil embolization of feeding vessels, translumbar coil embolization of the endoleak nidus and injection of liquid embolics or thrombin into the nidus.
- The Onyx™ Liquid Embolic System (LES) is an ethylene vinyl alcohol copolymer, previously reported to be successful in translumbar embolization of type II endoleaks.

Study objective

To report a single-center study in treating type II endoleaks with Onyx™, using a transarterial or translumbar approach.

Materials and methods

Study Design

- Single center, retrospective study of procedures conducted from August 1, 2006 to June 8, 2011.
- 101 type II endoleaks from 95 patients (6 patients had 2 separate type II endoleak) repaired using Onyx™ were included in the study.
- All patients presenting endoleak post-EVAR were included; patients found to have type I or type III endoleaks were excluded. 89 (93.7%) patients were male and 6 (6.3%) were female. Mean patient age was 77.6 years (range = 63-93 years).

Procedure

- If there was a feasible transarterial route via collateral pathways to the endoleak channel within the aneurysm sac, then a transarterial embolization was attempted. If there was incomplete apposition of the iliac limb of the stent graft to the iliac artery wall, then an attempt was made to track a hydrophilic wire and catheter directly into the aneurysm sac between the stent graft and iliac artery wall.

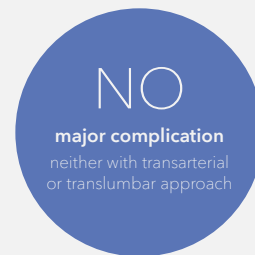- Once the aneurysm sac was accessed, the endoleak channel was catheterized, followed by digital subtraction angiography (DSA) to assess the involved vessels. Once the microcatheter was within the endoleak channel in the aneurysm sac, embolization was performed with Onyx™. The goal of embolization was to completely occlude the channel of flow and the involved vessels. Coil embolization of the entry vessels was also performed if Onyx™ did not adequately extrude into the vessel used to enter the aneurysm sac.

Translumbal Approach

If a direct route to the endoleak nidus was not achievable, a translumbal sac puncture and embolization was performed. Patients were placed in the prone position and general anaesthesia was administered. A 21-gauge styleted needle was used to directly access the aneurysm sac at or near the nidus of the endoleak. If the endoleak nidus was not directly accessible, remote access was obtained. Embolization was performed using Onyx™. If the inferior mesenteric artery was involved, protective coil embolization was performed prior to liquid embolization.

Results

- A total of 65 endoleaks (64.4%) were embolized through a transarterial approach, and 36 (35.6%) were treated through a translumbal approach.
- Since initial attempts to treat all patients via common femoral access, 58 (65.9%) of 88 patients were successfully treated via transarterial route. However, of the last 13 cases, 12 (92.3%) were successfully embolized transarterially.
- All the endoleaks in the translumbal group were successfully accessed and complete embolization was achieved in all cases.
- No significant difference in efficacy in regard to either aneurysm sac behavior ($t = 0.13$, $P = 0.90$) or residual endoleak rate (chi-square analysis, $P = 0.21$) when comparing transarterial and translumbal approaches.



Follow-up imaging data for **transarterial Embolizations (n=29)**

Change in aneurysm size	n	%	Residual endoleak rate
Decrease by > 1cm ²	13	44.8%	2/13 (15.4%)
Stabilization (≤ 1cm ² change)	8	27.6%	3/8 (33.3%)
Increase by > 1cm ²	8	27.6%	7/8 (87.5%)
Total	29	100%	12/29 (41.4%)

Follow-up imaging data for **translumbal Embolizations (n=24)**

Change in aneurysm size	n	%	Residual endoleak rate
Decrease by > 1cm ²	11	45.8%	1/11 (9.1%)
Stabilization (≤ 1cm ² change)	7	29.2%	2/7 (28.6%)
Increase by > 1cm ²	6	25.0%	3/6 (50.0%)
Total	24	100%	6/24 (25.0%)

Follow-up imaging data for **all type II Endoleaks (n=53)**

Change in aneurysm size	n	%	Residual endoleak rate
Decrease by > 1cm ²	24	45.3%	3/24 (12.5%)
Stabilization (≤ 1cm ² change)	15	28.3%	5/15 (33.3%)
Increase by > 1cm ²	14	27.7%	10/14 (71.4%)
Total	53	100%	18/53 (34.0%)

Conclusions

Transarterial access of the endoleak nidus is feasible, and controlled embolization is possible using Onyx™. Furthermore, Onyx™ appears effective in long-term stabilization of aneurysm sac size and in preventing residual endoleaks.

Medtronic


Europe
Medtronic International Trading Sàrl.
Route du Molliou 31
Case postale
CH-1131 Tolochenaz
www.medtronic.eu
Tel: +41 (0)21 802 70 00
Fax: +41 (0)21 802 79 00

See the device manual for detailed information regarding the instructions for use, indications, contraindications, warnings, precautions, and potential adverse events. For further information, contact your local Medtronic representative and/or consult the Medtronic website at medtronic.eu.

UC202300961a-emo-green-paper-endoleaks-dr-massis-en-we-8272797
© 2022 Medtronic. All Rights Reserved.

Reference

Massis K et al. "Treatment of Type II Endoleaks With Ethylene-Vinyl-Alcohol Copolymer (Onyx)". *Vascular and Endovascular Surgery* 2012; 46(3):251-257



Go to article